

Ligament Reconstruction in Congenital Absence of the Anterior Cruciate Ligament

Jorge Chahla, Cecilia Pascual-Garrido & Scott A. Rodeo

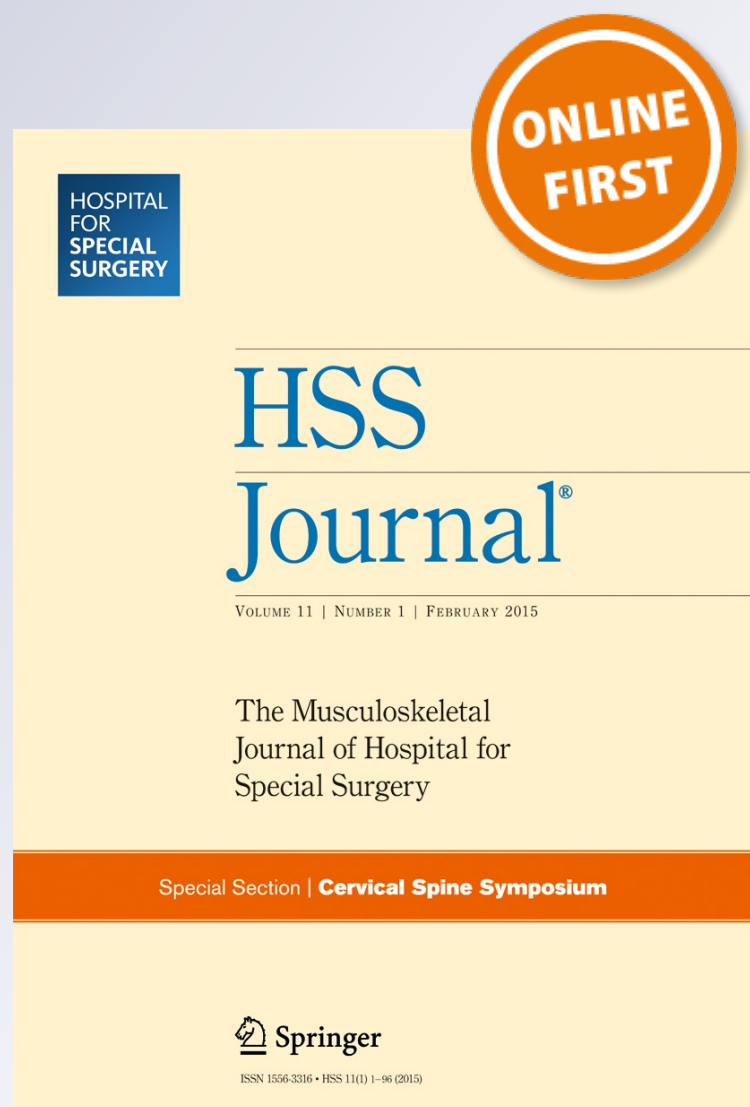
HSS Journal®

The Musculoskeletal Journal of Hospital
for Special Surgery

ISSN 1556-3316

HSS Jnl

DOI 10.1007/s11420-015-9448-6



Your article is protected by copyright and all rights are held exclusively by Hospital for Special Surgery. This e-offprint is for personal use only and shall not be self-archived in electronic repositories. If you wish to self-archive your article, please use the accepted manuscript version for posting on your own website. You may further deposit the accepted manuscript version in any repository, provided it is only made publicly available 12 months after official publication or later and provided acknowledgement is given to the original source of publication and a link is inserted to the published article on Springer's website. The link must be accompanied by the following text: "The final publication is available at link.springer.com".

CASE REPORT

Ligament Reconstruction in Congenital Absence of the Anterior Cruciate Ligament

A Report of Two Cases

Jorge Chahla, MD · Cecilia Pascual-Garrido, MD · Scott A. Rodeo, MD

Received: 4 February 2015/Accepted: 22 April 2015
© Hospital for Special Surgery 2015

Keywords congenital absence · anterior cruciate ligament · ACL reconstruction · dysplasia

Introduction

Congenital absence of the anterior cruciate ligament (ACL) is an extremely rare condition (0.017 per 1000 live births) [12]. It has been reported as an isolated entity [1, 14] or associated with other abnormalities such as congenital femoral deficiency, fibular hemimelia, scoliosis, hip dysplasia, and dysplasia of the tibial intercondylar eminence [4, 9, 10, 14]. It was first reported by Giorgi [8] in 1956 in a radiographic study, and since then, several case reports have been published [4, 11]. Most reports describe patients with no complaints of instability (despite having positive objective instability tests) but pain due to osteoarthritis of the medial femorotibial joint [12]. Individuals with this condition may

not have symptomatic instability if they are able to use muscle forces to provide knee stability. The cases reported with symptomatic instability are likely due to an event that may alter the knee homeostasis making the ACL deficiency manifest [15]. Given the rarity of the condition, there is no consensus regarding the optimal therapeutic approach, although most studies conclude that non-surgical options are the appropriate management despite early degenerative joint disease. Anterior cruciate ligament reconstruction is indicated when symptoms of instability appear [6].

This is a report on two cases of congenital absence of the ACL, one with a femoral length discrepancy and another with a lateral femoral condyle hypoplasia and posterior cruciate ligament (PCL) dysplasia.

Case Report

Case 1

A 17-year-old male was referred to us for pain and instability in his right knee. His past medical history was notable for a right leg lengthening procedure done at the age of 14 with an Ilizarov frame achieving approximately 1.5 in. of lengthening of the right femur. Manipulation of the right knee was required following this procedure, during which he suffered a fracture at the corticotomy site and underwent surgery at an outside institution and healed satisfactorily. Upon removal of the frame 2 months later, he gradually resumed activities and returned to sport (baseball) for a year with no knee problems. However, by the next year, he began having pain and swelling in the knee. There was no distinct trauma. He was initially seen in another institution and diagnosed with an acute ACL tear, after which he was referred to us for further evaluation and management. At

Electronic supplementary material The online version of this article (doi:10.1007/s11420-015-9448-6) contains supplementary material, which is available to authorized users.

J. Chahla, MD (✉)
Orthopedic Department, Sports Medicine, Buenos Aires British Hospital,
Perdriel 74, Buenos Aires, Argentina
e-mail: jachahla@msn.com

C. Pascual-Garrido, MD
Orthopedic Department, Sports Medicine, University of Colorado,
Boulder, CO 80304, USA

S. A. Rodeo, MD
Orthopedic Department, Sports Medicine and Shoulder Service,
Hospital for Special Surgery,
535 East 70th Street,
New York, NY 10021, USA

the time of consultation, he had both pain and a sense of instability when he pivoted on his right leg. He had not had any recurrent swelling or episodes of catching or locking.

Physical Examination

Inspection with the patient standing demonstrated neutral alignment. With the patient supine, measurement from the anterior superior iliac spine to the medial malleolus demonstrated equivalent leg lengths. Inspection of the right knee showed healed incisions over the distal lateral femur, as well as pin sites. Patellar tracking was anatomic with no crepitus. There was only a trace effusion, and there was normal patellar mobility with no patellar apprehension. Knee motion was 0–140°, with positive Lachman and anterior drawer tests, a glide in pivot shift test, and intact varus and valgus stability. He had medial and lateral joint line tenderness. There was no increase in external rotation. Sensory, motor, and vascular examination was intact.

Images

Plain radiographs demonstrated irregularity in the right distal femur in the distal diaphyses where there was a procurvatum deformity and mild patella baja. The intercondylar notch appeared stenotic on the flexion PA view. Joint space was well maintained (Fig. 1a–c).

Magnetic resonance imaging (MRI) demonstrated apparent absence of the ACL, hypoplasia of the tibial spines, an extremely stenotic intercondylar notch, and a dysplastic femoral trochlea, as well as abnormal articular cartilage over the medial patellar facet. The posterior cruciate, lateral collateral, and medial collateral ligaments were present. Both menisci appeared largely normal, with only mild signal abnormality in the posterior horn of the medial meniscus. There was a bone marrow edema pattern in the anterior margin of the lateral femoral condyle but no corresponding lesion on the tibial

side. The procurvatum deformity in the distal femur was also evident (Fig. 2a–c). Based on these findings, an arthroscopic ACL reconstruction was proposed in order to treat the symptomatic instability.

Surgical Procedure

Examination under anesthesia demonstrated a grade 2B Lachman, 2+ pivot shift, and negative posterior drawer. Arthroscopic inspection demonstrated absence of the anterior cruciate ligament with hypoplastic tibial eminences. The popliteus tendon appeared atretic (Fig. 3a, b). The lateral meniscus appeared to be nearly circular, with tissue extending from the posterior horn of the lateral meniscus all the way up toward the anterior horn of the meniscus. There was a horizontal tear of the posterior horn of the medial meniscus which was treated with partial meniscectomy. Articular cartilage was normal in all three compartments.

ACL reconstruction was performed using a bone-patellar tendon autograft. The patellar tendon graft was harvested in standard fashion. A motorized shaver was used to create an intercondylar notch with normal shape and size. Bone tunnels (10-mm diameter) were made on both the tibial and femoral sides. The graft was passed and then fixation was performed using an interference screw on the femoral side and the sutures were tied over a button on the tibial side. After graft fixation, anterior drawer, Lachman, and pivot shift tests were negative and arthroscopic inspection demonstrated good graft tension and position with no intercondylar notch impingement in full extension.

Follow-Up

The patient is currently in his first year of follow-up, making good progress in his rehabilitation.

Case 2

A 30-year-old female patient presented with occasional episodes of pain in the medial side of the right knee, instability,

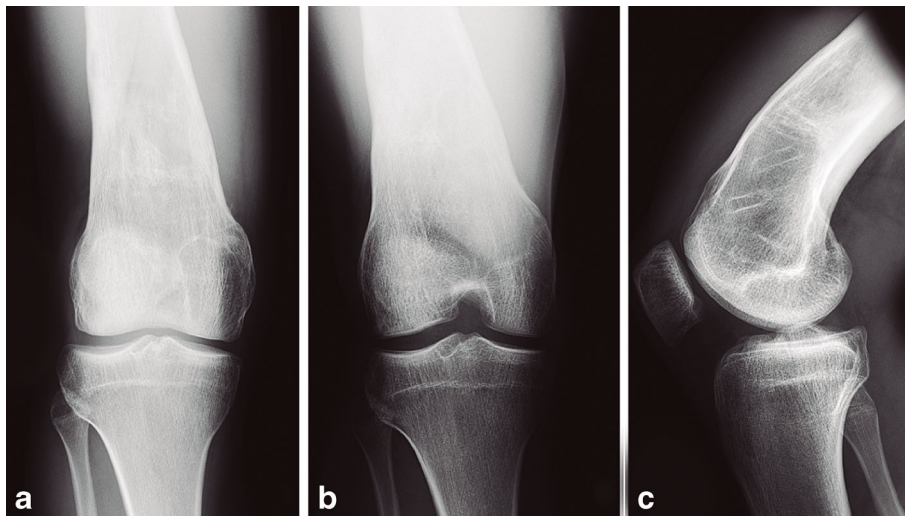


Fig. 1. Plain radiographs. **a** PA view: the image shows a stenotic intercondylar notch. **b** Flexion PA view. **c** Lateral view: there is an evident procurvatum in the lateral view.

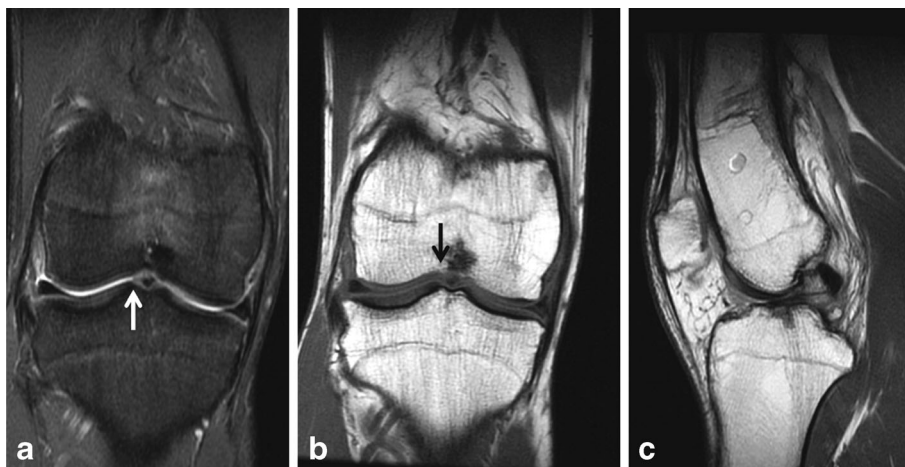


Fig. 2. Magnetic resonance images. **a** Fat saturation coronal view. **b** T1 coronal view. **c** T1 sagittal view. There is an apparent absence of the ACL, hypoplasia of the tibial spines (*white arrow*), an extremely stenotic intercondylar notch, and a dysplastic femoral trochlea (*black arrow*).

swelling, and locking. She had undergone a prior medial patellofemoral ligament reconstruction in the contralateral knee with a good result. The symptoms in the right knee began approximately 2 years after the left knee reconstruction.

Physical Exam

Bilateral valgus alignment was evident. There was no obvious effusion. She had patellar hypermobility and patellar apprehension. Range of motion was 0–140° of flexion. Valgus and varus stability were intact. Lachman was a grade 2B with loss of the endpoint. Anterior drawer and pivot shift were hard to evaluate due to guarding. There was medial joint line tenderness.

Images

Anteroposterior x-ray of the knee showed mild abnormality in the morphology of the lateral tibial plateau and lateral femoral condyle with an apparent hypoplasia of the lateral femoral condyle (Fig. 4a, b). MRI demonstrated a deficient intercondylar notch and an absent ACL. The posterior cruciate ligament (PCL) was small and vertically oriented (Fig. 5). There was no evidence of recent tibial translation

but a tear in the posterior horn body segment of the medial meniscus.

Surgical Procedure

The patient underwent arthroscopic surgery for treatment of the meniscus tear and ACL and medial patellofemoral reconstruction. Examination under anesthesia demonstrated a grade 2B Lachman test and a 2+ pivot shift test. There was a negative posterior drawer. Collateral ligament stability was intact. There was patellar hypermobility.

Arthroscopic inspection demonstrated absence of the intercondylar notch, hypoplastic tibial eminences, and absence of the ACL. There was a dysplastic PCL. A bucket handle tear of the medial meniscus was evident. Cartilage was normal in all three compartments.

A notchplasty was performed to recreate an intercondylar notch (Fig. 6). ACL reconstruction was done using an Achilles tendon allograft through 11-mm bone

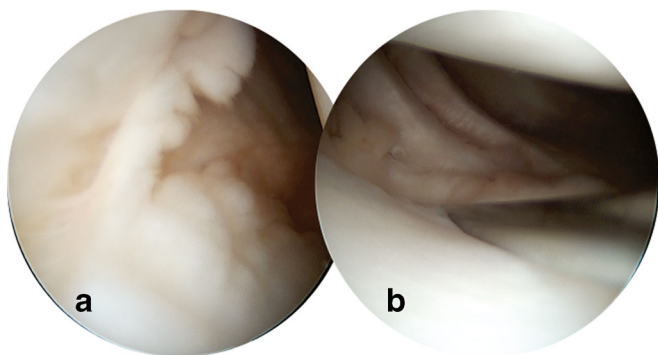


Fig. 3. Atretic popliteus tendon. **a** Arthroscopic inspection of lateral gutter. **b** Posterolateral inspection showing absence of the popliteus tendon.

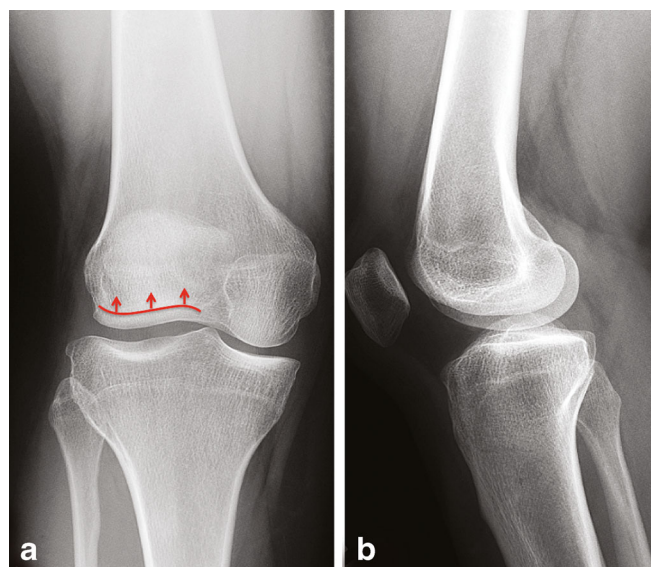


Fig. 4. Plain radiographs. **a** PA view. **b** Lateral view. Depressed lateral tibial plateau and a hypoplastic lateral femoral condyle (*red arrows*).

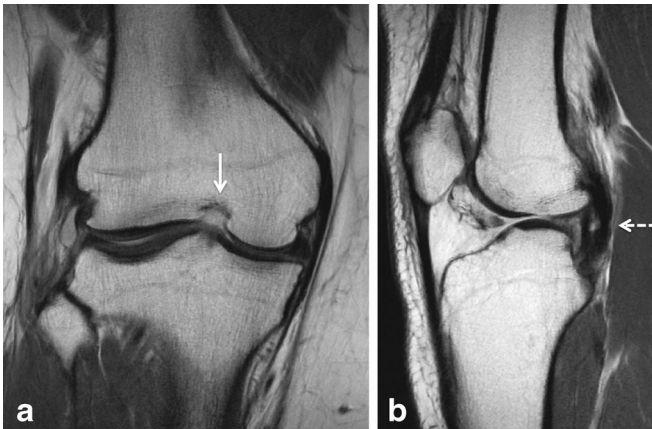


Fig. 5. Magnetic resonance image demonstrating **a** an absent ACL with a stenotic notch (*white arrow*) and **b** a thin and vertically oriented PCL (*dotted arrow*).

tunnels. Both femoral and tibial sides were fixed with interference screws. In addition to the interference screw, the sutures attached to the graft were attached to the tibia using a SwiveLock (Arthrex Inc, Naples, FL). Medial meniscus repair was carried out using three Fast-Fix (Smith and Nephew, Andover, MA) sutures. The medial patellofemoral ligament was then reconstructed using a posterior tibial tendon allograft. Isometry of the tunnel sites for the medial patellofemoral ligament (MPFL) reconstruction was verified. The allograft was fixed on the patellar side with two suture anchors. The femoral side fixation of the MPFL graft was done using a bioabsorbable interference screw in a 10-mm diameter bone tunnel.

Follow-Up

At 1-year follow-up, the patient reported overall improvement with no signs of instability. She had re-established full range of motion, with normal patellar mobility and stability, with a firm endpoint to lateral patellar translation. The patellar apprehension had been eliminated. Lachman and pivot shift were negative. She had returned to recreational activities.

Discussion

The structures of the knee are formed during the 7th to the 10th week of intrauterine life by direct condensation and

differentiation of the blastemal tissue of the intercondylar disc [16]. By approximately the 8th week (O'Rahilly stage 22), the knee resembles that of the adult [7], with the posterior cruciate ligament being the first ligament to become distinguishable. Dysplasia and/or absence of the ACL is reported to occur in 0.017 per 1000 live births [12]. Of note, there are no reported cases of an isolated PCL deficiency [16]. With absence of the ACL, the intercondylar notch and the tibial spines fail to develop since they lack the stimuli to grow [2]. Based on these findings, Manner [13] described a classification of the three main types of dysplasia: I) hypoplasia or aplasia of the ACL with a normal PCL, II) aplasia of the ACL and hypoplasia of the PCL, and III) aplasia of both cruciate ligaments. In our first case described, the patient presented with a type I aplasia, and in the second patient, there was a hypoplasia of the PCL concomitant with the absence of ACL (type 2). The etiology of this entity remains unknown; however, it is likely that genetic factors play a role, as it has been reported in monozygotic twins [15] and in several members of the same family [5].

In regard to the presentation of this pathology, patients with congenital ACL deficiency may not develop symptoms of instability, likely due to either compensatory mechanisms or a more sedentary lifestyle [15] in which this abnormality would not become apparent. Furthermore, there are some reports of grossly hypertrophied and anteriorly positioned meniscofemoral ligament of Humphrey which could play a role in diminishing instability symptoms in the setting of PCL deficiency [6].

Anterior cruciate ligament reconstruction is only indicated if the patient develops symptomatic instability. ACL reconstruction in these knees is more technically demanding due to the altered anatomy, including increased tibial slope, hypoplasia of the lateral femoral condyle, and a rounded posterior femoral condyle [5]. The pivot shift phenomena and resultant symptomatic instability may be more likely with a dysplastic lateral femoral condyle due to a shorter bony arc of tibiofemoral contact. These factors may challenge the successful results achieved in a primary ACL reconstruction [3]. Good results have been reported with ACL reconstruction surgery in these patients. For example, Sonn [15] reported two reconstructions in monozygotic twins with good results at 32-month follow-up and Gabos [6] reported four ACL reconstructions with 31-month follow-up with excellent results.

In conclusion, congenital ACL absence is a rare disease and is often misdiagnosed because it may be clinically silent for a long period of time, and symptoms may begin with minimal trauma. Conservative treatment has been the gold standard in most patients, with ACL reconstruction reserved for patients with symptomatic instability. The goals of ACL reconstruction in this setting are similar to routine primary ACL surgery: to restore knee stability, to re-establish more normal knee kinematics, and to prevent further degenerative joint disease. Continued follow-up of these patients is required to determine if we can achieve these goals.

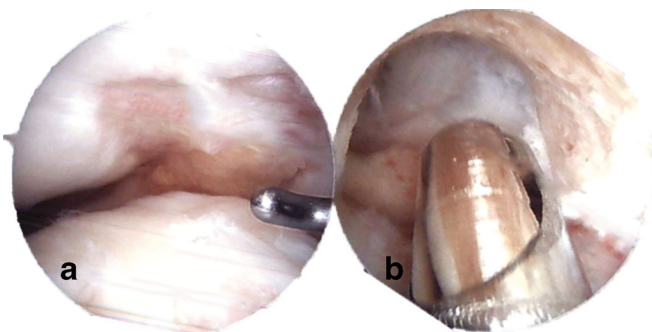


Fig. 6. **a** Stenotic intercondylar notch. **b** Result of the notchplasty.

Disclosures

Conflict of Interest: Jorge Chahla, MD and Cecilia Pascual-Garrido, MD have declared that they have no conflict of interest. Scott A. Rodeo, MD reports stock options with Rotation Medical and is a consultant of Cytori Therapeutics, Inc. outside the work.

Human/Animal Rights: All procedures followed were in accordance with the ethical standards of the responsible committee on human experimentation (institutional and national) and with the Helsinki Declaration of 1975, as revised in 2008 (5).

Informed Consent: Informed consent was waived from all patients for being included in the study.

Required Author Forms Disclosure forms provided by the authors are available with the online version of this article.

References

1. Barrett GR, Tomasin JD. Bilateral congenital absence of the anterior cruciate ligament. *Orthopedics*. 1988; 11(3): 431-4.
2. Berruto M, Gala L, Usellini E, Duci D, Marelli B. Congenital absence of the cruciate ligaments. *Knee Surg Sports Traumatol Arthrosc*. 2012; 20(8): 1622-5.
3. Carlouz H. Description and natural history of severe aplasia of the lower extremities. *Chir Pediatr*. 1978; 19(5-6): 306-21.
4. Dejour H, Neyret P, Eberhard P, Walch G. Bilateral congenital absence of the anterior cruciate ligament and the internal menisci of the knee. A case report. *Rev Chir Orthop Reparatrice Appar Mot*. 1990; 76(5): 329-32.
5. Frikha R, Dahmene J, Ben Hamida R, Chaieb Z, Janhaoui N, Laziz Ben Ayeche M. Congenital absence of the anterior cruciate ligament: eight cases in the same family. *Rev Chir Orthop Reparatrice Appar Mot*. 2005; 91(7): 642-8.
6. Gabos PG, El Rassi G, Pahys J. Knee reconstruction in syndromes with congenital absence of the anterior cruciate ligament. *J Pediatr Orthop*. 2005; 25(2): 210-4.
7. Gardner E, O'Rahilly R. The early development of the knee joint in staged human embryos. *J Anat*. 1968; 102(Pt 2): 289-99.
8. Giorgi B. Morphologic variations of the intercondylar eminence of the knee. *Clin Orthop*. 1956; 8: 209-17.
9. Hu J, Du SX, Huang ZL, Xia X. Bilateral congenital absence of anterior cruciate ligaments associated with the scoliosis and hip dysplasia: a case report and review of the literature. *Chin Med J (Engl)*. 2010; 123(8): 1099-102.
10. Johansson E, Aparisi T. Missing cruciate ligament in congenital short femur. *J Bone Joint Surg Am*. 1983; 65(8): 1109-15.
11. Kwan K, Ross K. Arthrogyposis and congenital absence of the anterior cruciate ligament: a case report. *Knee*. 2009; 16(1): 81-2.
12. Lee JJ, Oh WT, Shin KY, Ko MS, Choi CH. Ligament reconstruction in congenital absence of the anterior cruciate ligament: a case report. *Knee Surg Relat Res*. 2011; 23(4): 240-3.
13. Manner HM, Radler C, Ganger R, Grill F. Dysplasia of the cruciate ligaments: radiographic assessment and classification. *J Bone Joint Surg Am*. 2006; 88(1): 130-7.
14. Noble J. Congenital absence of the anterior cruciate ligament associated with a ring meniscus. *J Bone Joint Surg Am*. 1975; 57(8): 1165-6.
15. Sonn KA, Caltoun CB. Congenital absence of the anterior cruciate ligament in monozygotic twins. *Int J Sports Med*. 2014; 35(13): 1130-3.
16. Uthoff H.K. The embryology of the human locomotor system. Published: Springer-Verlag. 1990.