

Technical Note

Surgical Treatment of Gluteus Medius Tears Augmented With Allograft Human Dermis

Cecilia Pascual-Garrido, M.D., Ph.D., Maria T. Schwabe, M.P.H.S.,
Jorge Chahla, M.D., Ph.D., and Masahiko Haneda, M.D., Ph.D.

Abstract: Greater trochanteric pain syndrome can be caused by gluteus medius and minimus tendinopathy/tears and chronic trochanteric bursitis. Specifically, moderate-to-severe abductor tendon tears can cause severe lateral hip pain, limp, and abnormal gait. A variety of open and endoscopic techniques to treat glut abductors hip tears have been described. The use of scaffolds, such as acellular human dermal allograft, to augment tendon repair, already has been successfully reported in rotator cuff repairs of the shoulder. Still, the use of acellular human dermal allograft in the hip has been limited. However, there are some clinical scenarios in which augmentation of abductors hip tendon repair with scaffold is indicated. Chronic or massive gluteus tears or revision cases may benefit from augmentation with a scaffold. The purpose of this technical note and accompanying video is to describe our indications, pearls, and pitfalls of repair of moderate to severe gluteus tears via a minimally invasive technique augmented with acellular human dermal allograft.

Greater trochanteric pain syndrome defines a chronic or intermittent pain accompanied by tenderness to palpation overlying the lateral aspect of the hip and encompasses a range of causes, including gluteus medius and minimus tendinopathy/tears, trochanteric bursitis, and external coxa saltans.^{1,2} Abductor tendon tears can cause severe pain over the lateral aspect of hip, limp, and instability of hip joint. Several techniques have been described for repairing these abductor tears, including direct transosseous repairs,³⁻⁵ endoscopic repair techniques,^{6,7} Achilles tendon allograft,⁸ gluteus maximus muscle

transfers,^{9,10} and vastus lateralis muscle transfers.^{10,11} Both open and endoscopic techniques are viable surgical approaches to repairing abductor tendon tears in the hip, resulting in good-to-excellent functional results.¹² However, in complex cases such as revisions or massive tears, augmentation with a graft should be considered.^{5,7} The graft provides a scaffolding for abductors reattachment, allows coverage of any bare areas of the greater trochanter, decreases gap formation, and possibly increases load to failure. The aim of this technical note and accompanying video is to describe our surgical method of abductor repair augmented with a dermis allograft (ArthroFlex; LifeNet Health, Virginia Beach, VA) as well as indications, pearls, and pitfalls of this surgical technique.

Diagnosis

Diagnosis is based on the patient's history and clinical presentation. A history of several greater trochanter steroid injections to treat chronic bursitis or previous arthroplasty can help guide the clinician toward diagnosis. Patients often complain of lateral hip pain, limping, or limited mobility, especially in hip abduction. In addition, patients are unable to sleep at night, especially when trying to sleep on the affected side. The classification reported by Lachiewicz¹³ is commonly used to assess the tear (Table 1). Radiographs are usually unremarkable, and magnetic resonance imaging (MRI) should be performed in all cases of suspected abductor tendon tears. A

From the Department of Orthopaedic Surgery, Washington University School of Medicine, St. Louis, Missouri (C.P.G., M.S., M.H.); and Orthopaedic Surgery Sports Medicine, Rush University Medical Center, Chicago, Illinois (J.C.), U.S.A.

The authors report no conflicts of interest in the authorship and publication of this article. Full ICMJE author disclosure forms are available for this article online, as [supplementary material](#).

Investigation performed at the Department of Orthopaedic Surgery, Washington University School of Medicine, 660 South Euclid Avenue, Campus Box 8233, St. Louis, MO 63110.

Received May 24, 2019; accepted July 18, 2019.

Address correspondence to Cecilia Pascual-Garrido, M.D., Ph.D., Department of Orthopaedic Surgery, Washington University School of Medicine, 660 South Euclid Avenue, Campus Box 8233, St. Louis, MO 63110, U.S.A. E-mail: cpascualgarrido@wustl.edu

© 2019 by the Arthroscopy Association of North America. Published by Elsevier. This is an open access article under the CC BY-NC-ND license (<http://creativecommons.org/licenses/by-nc-nd/4.0/>).

2212-6287/19672

<https://doi.org/10.1016/j.eats.2019.07.014>

Table 1. Classification of the Abductor Tears

Group	Age	Symptom	Arthritis	Type of Tears
1	Elderly	Symptomatic (limp, lateral hip pain, and weakness of hip abduction)	Without arthritis	Degenerative or traumatic tears
2	Middle age to elderly	Asymptomatic	Patients undergoing arthroplasty for OA or fractured neck of the femur	Abductor muscle complex tears
3	Middle age to elderly	Symptomatic (limp, lateral hip pain, and weakness of hip abduction)	Arthritis	Avulsion or failure of repair of abductor muscles following THA performed through the anterolateral approach

OA, osteoarthritis; THA, total hip arthroplasty.

previous report has shown that MRI remains the gold standard for diagnosis of hip abductor tears, with reported specificity of 95% and sensitivity of 73%.¹⁴ Recently, the classification reported by Goutallier et al.¹⁵ and Fuchs et al.,¹⁶ which is based on the amount of fat surrounding the tendon and muscle for the rotator cuff tears of the shoulder, has been applied to evaluate abductor tendon tears and their prognosis following surgical treatment.¹⁷ Most importantly, the MRI helps identify good candidates for surgery. In those patients with secondary atrophy or fatty infiltration of the muscle, this surgery should not be performed, as it will not improve the patient's limp. In those cases, a gluteus maximus muscle transfer should be considered.¹⁸

Indications

Typically, management begins with short-term use of a nonsteroidal anti-inflammatory drug, physical therapy for stretching and strengthening, activity

modification, and judicious use of corticosteroid plus local anesthetic injection into the tender trochanteric bursa. When the patient is unresponsive to nonsurgical care and a tear is visible on MRI, surgical repair should be considered early, particularly before the onset of serious fatty muscle atrophy. Specifically, MRI helps identify the location of the tear as well as assesses retraction and associated bursitis. In particular, the sagittal view is very helpful to identify the type of the tear and location in the anteroposterior plane. In addition, in revision cases, MRI helps identify previous anchors and remnant tissue to repair (Fig 1).

Surgical Technique

Patient Positioning

The procedure is performed with the patient in lateral decubitus assisted with a bean bag. Surgery is performed with the patient under general anesthesia with

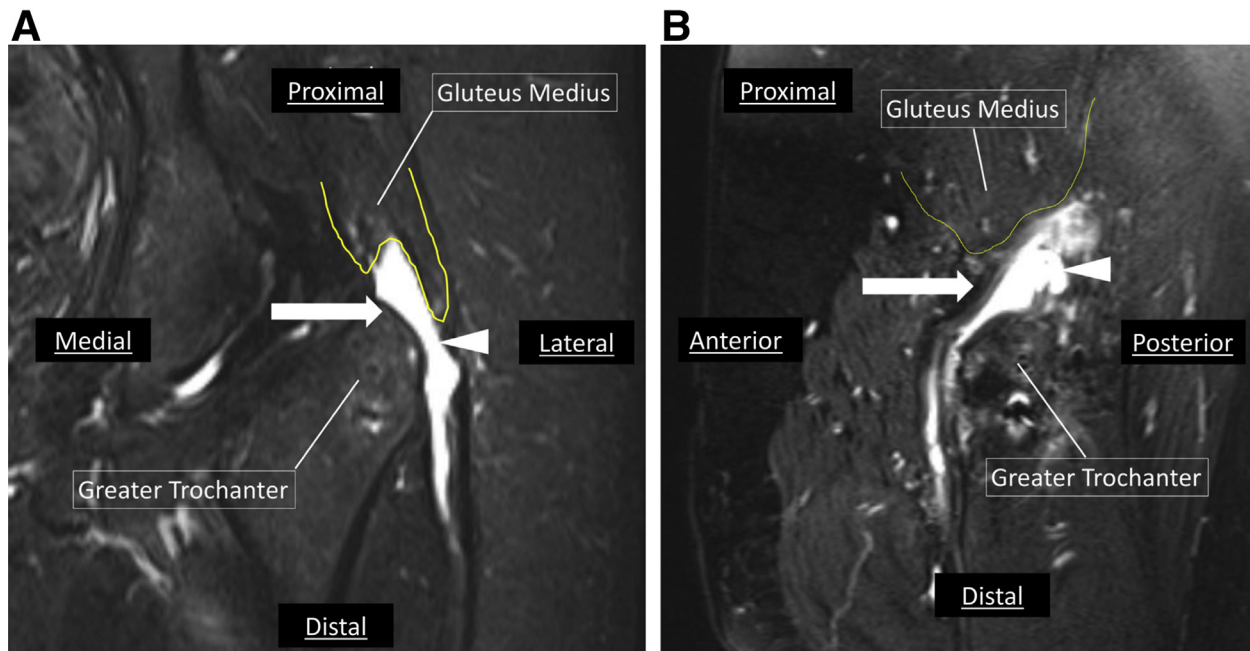


Fig 1. Magnetic resonance imaging (MRI) scan demonstrating a gluteus medius tear (arrows and arrowheads) of the left hip with severe bursal fluid in the (A) coronal view, (B) sagittal view. Severe retraction of the tendon affecting middle and posterior portion is observed. MRI should be used to exactly locate the tear and assess the degree of retraction. Especially, the sagittal view is critical to help locate the tear in the anteroposterior aspect of greater trochanter. Yellow line = proximal retraction of the gluteus medius.

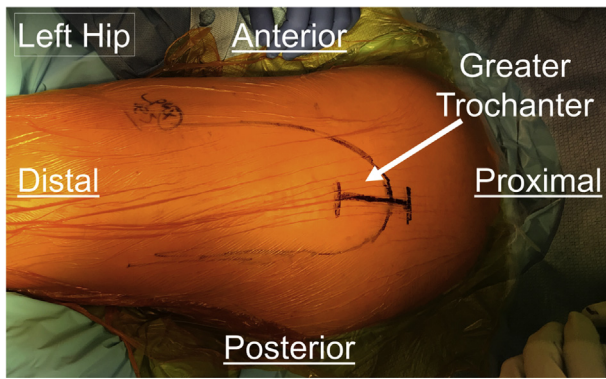


Fig 2. Image demonstrating the patient positioning in the lateral decubitus for a left hip. It is important to pad the patient adequately to prevent nerve compression during procedure. Palpate the greater trochanter and, using a marking pen, mark the incision (arrow). The incision should be centered in the greater trochanter (approximately 5-8 cm long). Extension proximally depends on severity of retraction.

complete muscle relaxation. An axillary roll is positioned underneath the patient at the level of the nipples; the bottom leg should be padded with pillows to avoid peroneal nerve palsy and the bottom arm needs to be padded to avoid ulnar neuropathy.

Perform the Skin and Iliotibial Band Incision, and Identify the Gluteus Tear

Preparation and draping are performed in the standard sterile fashion, ensuring that area corresponding to the greater trochanter is exposed in the field. Incision is performed over the greater trochanter area and carried on through the subcutaneous tissue (Fig 2). The fascia lata is identified and incised longitudinally over the greater

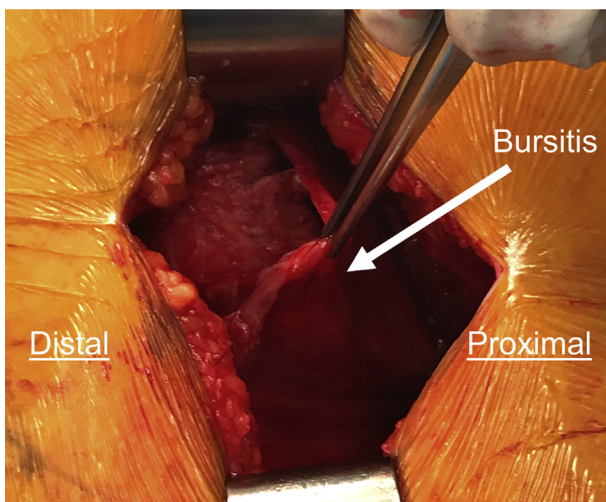


Fig 3. Intraoperative picture demonstrating a deeper dissection (after incising the fascia lata) on a left hip. The pick-up is showing the severe bursitis (arrow). It is very common to see associated bursitis in chronic glut tears. This bursa has to be removed to remove inflammation and potential source of pain.

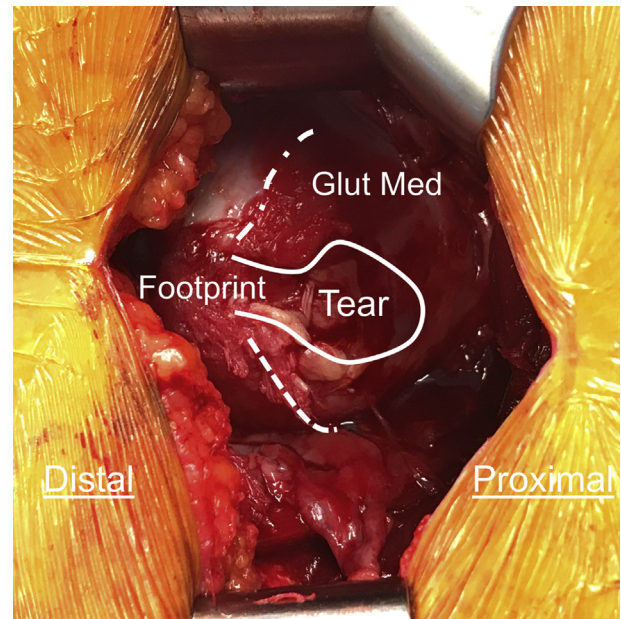


Fig 4. Left hip. After the iliotibial band is incised and bursa is removed, the gluteus tear can be identified. Intraoperative picture demonstrating identification of the gluteus (glut) medius tear. In this case, the tear was located in the medial portion of the glut medius. Retraction is observed resulting in bone footprint exposure.

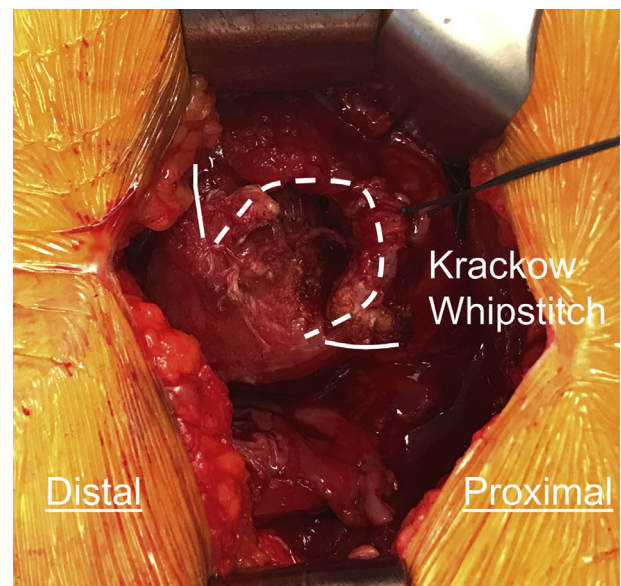


Fig 5. Left hip. Using an Alice or Kocher instrument, the tendon is identified and pulled distal. The free end of the tendon is whipstitched with a Krackow type configuration to safely secure the end of the tendon and perform a proper release from the surrounding soft tissue. Release and mobilization of the muscle and corresponding tendon is performed to allow proper mobilization and reduction to the footprint. It is very important to take the time to release adhesions above and under the tendon.

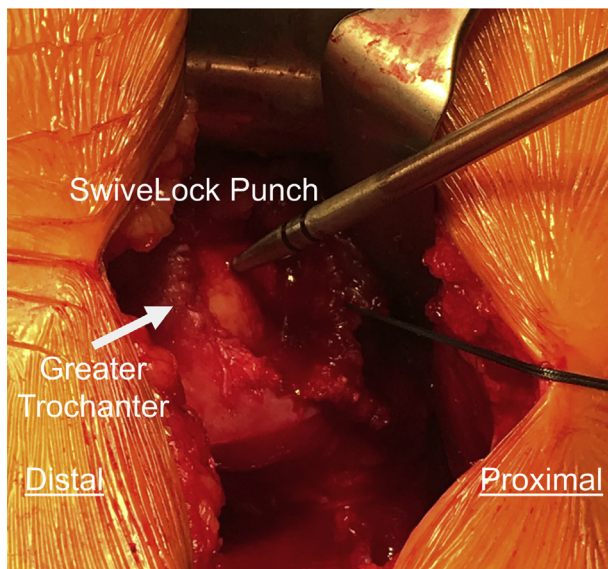


Fig 6. Left hip. Footprint is identified and the bony bed is carefully prepared. Use a rasp to generate bone bleeding. A punch is used to prepare the bony bed for the 2 proximal anchors. The affected hip is positioned at 20° of abduction and neutral rotation and a flexed knee resting on a Mayo stand to facilitate tendon approximation under minimal tension.

trochanter. Often times, there is severe bursitis that needs to be removed (Fig 3). The tear is identified over the trochanteric attachment (Fig 4). Sometimes the tear is difficult to identify secondary to significant scar tissue. In these cases, the sagittal MRI view will help identify the correct location of the tear in the anteroposterior plane.

Mobilize the Tendons

Release and mobilization of the muscle and corresponding tendon are performed to allow proper reduction to the footprint. The free end of the tendon is whipstitched with a Krackow type configuration (NO. 2

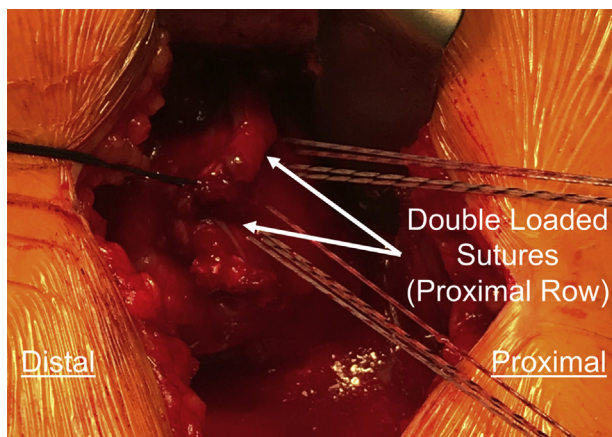


Fig 7. Left hip. Proximal row anchors were inserted (arrows: 4.75-mm biotenodesis anchors, double loaded, SwiveLock C; Arthrex). All suture limbs (total of 8, 4 from each corresponding anchor) are passed through the tendon using a free needle.

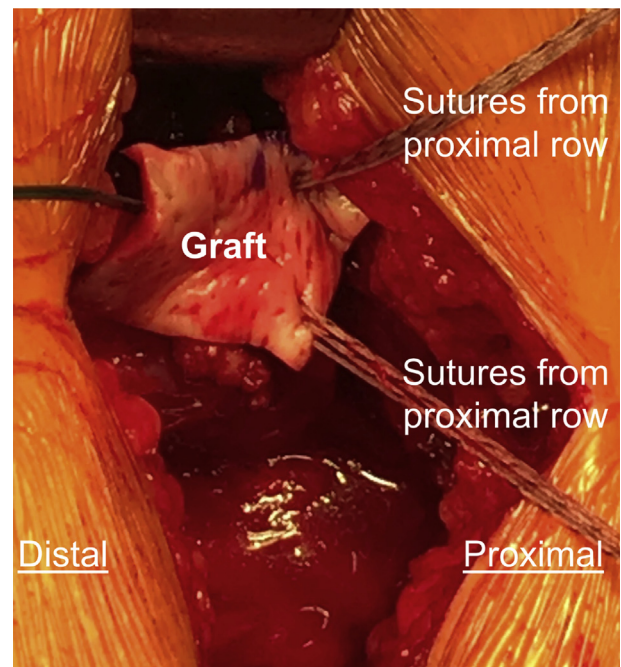


Fig 8. Left hip. The dermis graft (Human Dermal patch, ArthroFlex; LifeNet Health) is placed in an “on-lay type” by placing the graft above the repair. Suture limbs (total of 8) from the proximal suture anchors are passed through the graft. These suture limbs were passed through the tendon and now are being passed through the graft. Once this is done, the suture limbs are tied down.

ETHIBOND; Ethicon Inc., Cincinnati, OH) to pull traction and perform the release of all adhesions and permit advancement onto the trochanter and closure of the gap with the least-possible tension (Fig 5). A rongeur is used to remove the adhesions under the surface of the glut and to prepare a good bleeding footprint in the greater trochanter.

Preparation of the Footprint in the Greater Trochanter Area

The greater trochanter area should be prepared before the anchors are drilled. Using a rasp, the insertion site on the greater trochanter is scarified to a fresh bleeding bony surface. The affected limb should be maintained in approximately 20° of abduction and neutral rotation with the leg and the flexed knee resting on a Mayo stand to facilitate tendon approximation under minimal tension.

Locate the Insertional Site of the Tendons and Place the Holes and Suture Anchors Into the Footprint

A punch is used to prepare the bone for 2 proximal anchors, in the anterior medial aspect of the greater trochanter and as close as possible to the normal insertion (Fig 6). Then, two 4.75-mm SwiveLock C anchors (Arthrex, Naples, FL), double loaded with suture tape, are

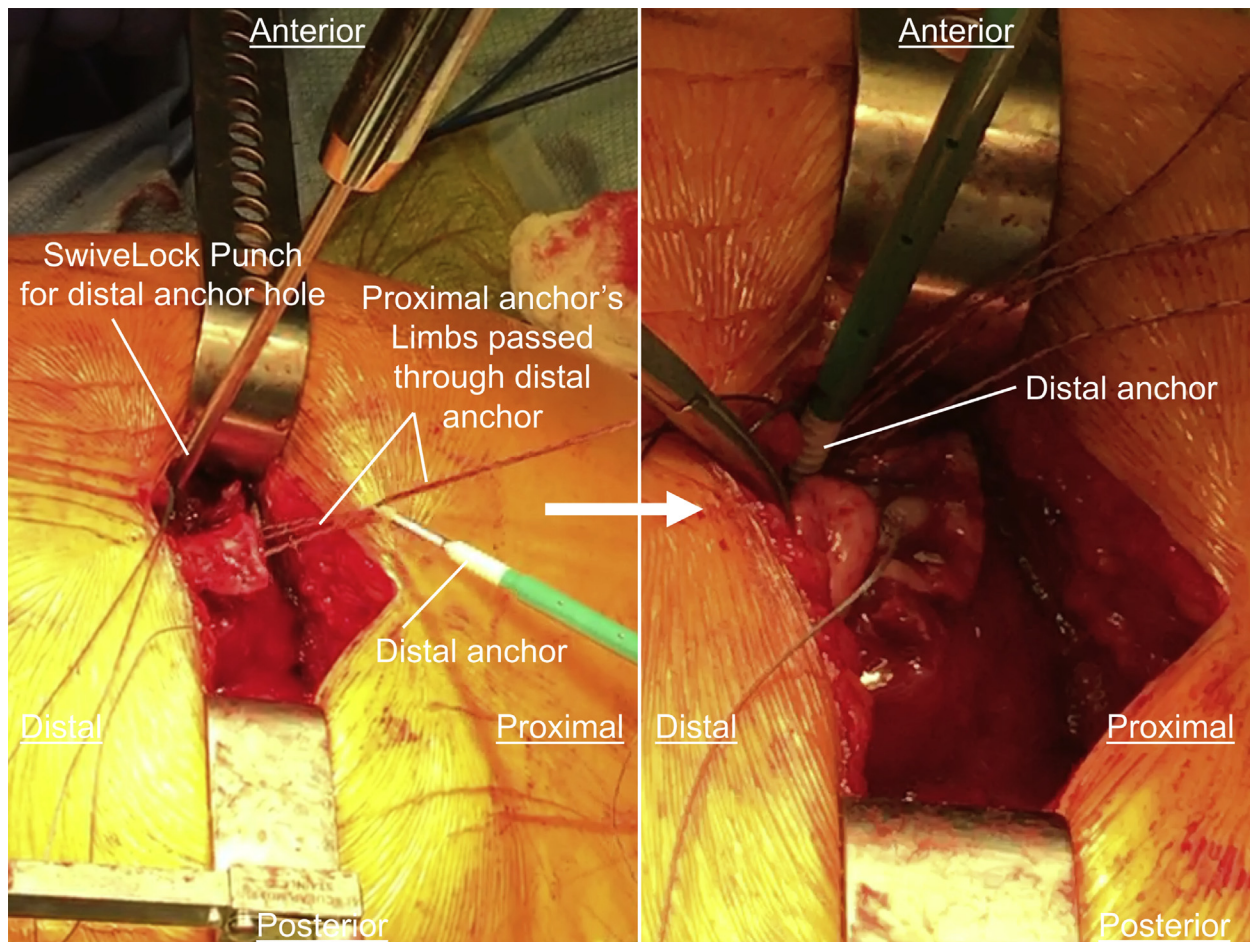


Fig 9. Left hip. A punch is used to perform the 2 distal bone holes. Suture limbs from the proximal anchors were passed into the eyelet of the distal anchors row in a SpeedBridge configuration. To perform the SpeedBridge, 2 tails from each proximal anchor are passed through the eyelet of corresponding distal anchor. A total of 4 suture limbs will be passed through the eyelet of one distal anchor. The eyelet, loaded with 4 suture limbs (2 limbs from one proximal anchor and 2 limbs from second proximal anchor) of the distal anchor is brought to the bone. Tension is applied so that the tissue along with the graft are reduced and compressed against the bone. The tails are then cut with a cutter. The steps are repeated for the second distal anchor.

inserted into the corresponding prepared proximal row holes until the anchor body contacts the bone.

Reattach the Tendons

Both tails of the suture tape corresponding to each anchor (total of 8 suture limbs) are passed through the tendon using free needles (Fig 7). The sutures should be passed independently one by one.

Graft Preparation

The ArthroFlex Human Dermis (ArthroFlex; LifeNet Health) is brought into the field. An on-lay augmentation is performed using ArthroFlex Human Dermis covering the gluteus medius and greater trochanter. A template of the defect is made by placing the graft into the defect. A marking pen is then used to identify the appropriate size of the graft, which is trimmed

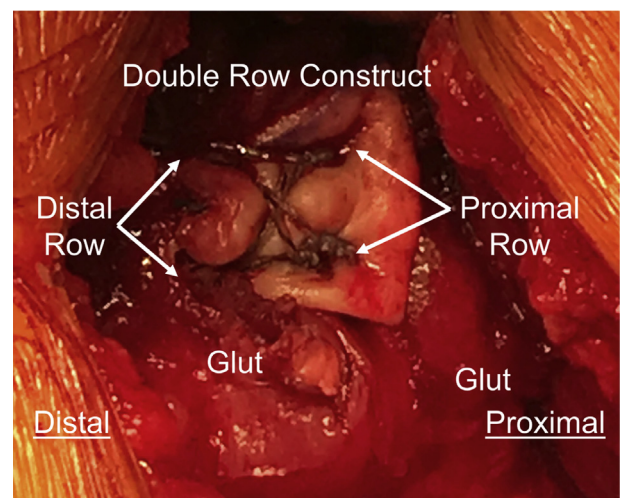


Fig 10. Left hip. SpeedBridge repair is observed.

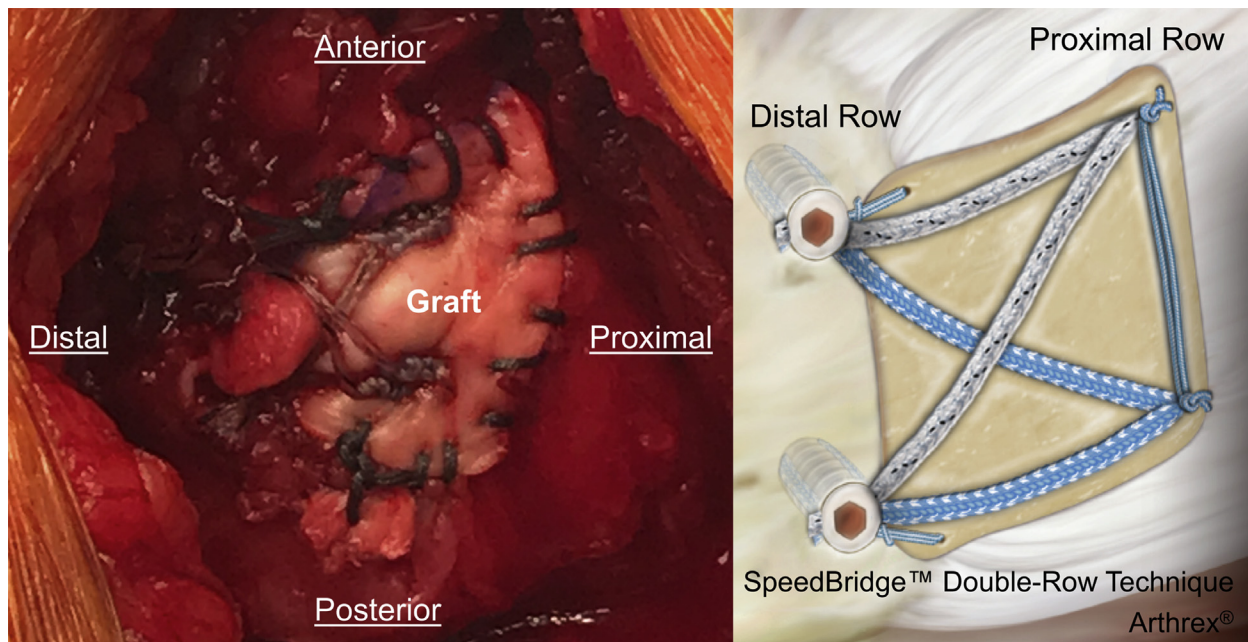


Fig 11. Left hip. SpeedBridge configuration with an “on lay dermis technique” is observed. A continue suture (No. 2 ETHIBOND; Ethicon Inc.) is used to reinforce repair.

accordingly in the back table. Then, the suture limbs from the proximal SwiveLock anchors (total of 8 suture limbs) that were passed through the tendon are now passed through the ArthroFlex Human Dermis (Fig 8). Once the suture limbs are passed through the tendon and graft, the sutures are tied down. It is important that the graft together with the tendon are reduced nicely into the footprint. Make sure that the knots are tied down next to the bone so there is no gap left between the anchor and the tendon.

Place the Distal Anchors on the Footprint in a SpeedBridge Configuration

The second row is prepared by punching 2 holes in the distal aspect of the repair (distal row) (Fig 9). Four suture limbs from each corresponding proximal row, (SpeedBridge configuration; Arthrex), are introduced in the SwiveLock C's, eyelet of the corresponding distal anchors (4 suture limbs per eyelet). The eyelet, loaded with 4 suture limbs from the proximal row, of the implant is brought to the bone. Tension is applied so

Surgical Steps

1. Utilize MRI (sagittal view) to assess exact location of the tear (Figure 1)
2. Position adequately the patient (Figure 2)
3. Incision over the tip of the greater trochanter (Figure 2)
4. Incised subcutaneous tissue and ITB (Iliotibial band) (Figure 3)
5. Identify tear and crackow it with an No.2 Ethibond (Figure 4, 5)
 1. Release adhesions
 2. Reduce tendon to the foot print
6. Prepare footprint (Figure 4)
7. Drill proximal row (#2)
 1. Limbs are passed through tendon and graft and tied down (Figure 6-8)
 2. Do not cut the limbs!
8. Drill Distal Row (#2)
 1. Limbs from proximal anchors row (total of 8) are passed through eyelet of the distal anchors
 2. 4 limbs in each corresponding eyelet (SpeedBridge configuration)
 3. Reduction of the graft and tendon while introducing the distal anchors (Figure 9, 10)

Fig 12. Surgical step-by-step bullets. (ITB, iliotibial band; MRI, magnetic resonance imaging.)

Table 2. Step by Step of the Technique

Step	Details
1. Skin and ITB incision and identifying the gluteus tear	Place the patient in the lateral decubitus position, mini-incision over the tip of the greater trochanter area, and then identify the extent of the gluteus tear (Figs 2, 3, and 4).
2. Mobilizing the tendons	Mobilize the tendon to release and reduce tendon to the footprint, and whipstitch the free end of the tendon with Krackow stitch (Fig 5).
3. Cleaning the footprint of the greater trochanter	Curette or rasp is used to induce a bleeding bony surface on the footprint.
4. Locating the insertional site of the tendons and placing the holes and suture anchors into this footprint	Identify the area of the footprint; two 4.75-mm anchors double loaded with suture tape should be placed in the footprint defining the proximal row (Fig 6).
5. Reattaching the gluteus medius tendon	Sutures tails from corresponding proximal anchors are passed through the gluteus medius tendon (Fig 7).
6. Graft preparation	Use the proximal suture limbs, pass them through the graft and trim of excessive graft (Fig 8). Tie down the sutures.
7. Place the distal anchors on the footprint and SpeedBridge configuration	Proximal suture limbs are passed through distal anchors eyelet, and place the anchors in distal row. They should be passed in SpeedBridge configuration (Figs 9, 10, and 11).
8. Reinforce repairing	Continues suture is used to suture the periphery of the graft with adjacent tendon and muscle (Fig 11).
9. Postoperatively	Patient is placed in a hip brace for 3 weeks, then progresses to full weight-bearing, and begins physical therapy at 6 weeks postsurgery.

ITB, iliotibial band.

that the tissue along with the graft are reduced and compressed against the bone. The driver is then completely advanced into the bone beyond the first laser line until the anchor body contacts bone. The anchor is then inserted until body is flush with the bone. The suture tails are then cut with a cutter. The steps are repeated for the second distal anchor (Figs 10 and 11).

Reinforce Repairing and Closing of the Wound

A continuous No. 2 ETHIBOND is used to suture the graft at its periphery to reinforce repair (Fig 11). There should not be bare areas of bone left over the trochanteric region. Irrigation is performed profusely. Closure of the fascia lata and rest of the superficial surgical wound is performed.

Step-by-step descriptions of the technique, equipment, pearls, pitfalls, advantages, disadvantages, risks, and limitation of this technique are shown in (Fig 12) and the corresponding tables and video (Tables 2, 3, 4, and 5 and Video 1).

Postoperative Guidelines

The patient is advised to use a hip brace and assisted crutches. The hip brace is set to 0° extension, 90° of flexion, neutral rotation, and 20° of abduction. The brace is used 24/7 for 3 weeks following surgery. The

brace can be removed to shower and to go to the bathroom. The patient is indicated to be toe-touch weight bearing (20% flat foot) for the first 3 weeks following surgery. At 3 weeks postoperatively, the patient will start to progress to full weight bearing and the hip brace will be indicated to be used only at night. Physical therapy it started 6 weeks postsurgery.

Discussion

We have described a minimally invasive surgical technique for the treatment of gluteus medius tears augmented with ArthroFlex, acellular human dermal allograft. Various techniques have been described for repair of the abductor tendon tears including direct transosseous repairs,³⁻⁵ endoscopic repair techniques,^{6,7} Achilles tendon allograft,⁸ gluteus maximus,^{9,10} and vastus lateralis muscle transfers.^{10,11} Vastus lateralis and glut max transfers are mostly indicated in patients with chronic glut tears and associated muscle atrophy.¹⁸ Endoscopic repairs require extensive arthroscopic training and have limitations in visualization and capacity of reducing the tendon to the footprint in chronic cases with severe adhesions.¹⁹ Reconstruction with the Achilles tendon allografts is expensive and not readily available in centers without appropriate human tissue licensing arrangements in place.⁸

Surgical technique and reported outcomes following abductors repair augmented with dermis allograft have been minimally reported.^{5,7,8,20,21} The advantages of using a synthetic dermis graft include availability and being technically easy to use. Rao et al.⁵ reported 12 hips with abductor tears treated with open repair

Table 3. List of the Crucial Pieces of Equipment for This Technique

Name	Brand Name	Manufacturer
Dermis allograft	ArthroFlex	LifeNet Health
Yarn	No. 2 ETHIBOND	Ethicon Inc.
Anchor	4.75-mm SwiveLock C anchor	Arthrex

Table 4. Pearls and Pitfalls

Pearls	Pitfalls
<ul style="list-style-type: none"> • Debride native footprint of medius to create a bleeding surface for healing. • Establish footprint for adequate sizing of the graft after repair. • Apply slight tension to graft when reducing it to the bone to ensure good contact with tendon. • Compliance of postoperative instructions while the graft is healing. 	<ul style="list-style-type: none"> • Be sure to resect sufficient bursa to allow visualization of the tendon. • Perform release of adhesions to make sure that the tendon can be reduced to the footprint. • Keep instrument in place after removing bone punch to facilitate anchor placement. • Do not neglect to abduct the hip 20° to relieve gluteal tension. • Failing to maintain suture management while fixating the graft.

Table 5. Advantages, Disadvantages, Risks, and Limitation

Advantages	Disadvantages
<ul style="list-style-type: none"> • Technique allows a good visualization. • Augments tendon repair in thin and degenerative tendons or revision cases. • Reproducible technique. • Acellular human dermal allograft provides immediate strength to repair while healing. 	<ul style="list-style-type: none"> • Graft and anchor expenses. • Strict patient compliance with postoperative restrictions required during the healing phase, including weight-bearing and wearing a hip protector.
Risks	Limitation
Deep vein thrombosis, inherent risks of surgery (infection, nerve injury).	No long-term clinical outcomes have been reported with this technique yet.

augmented with acellular human dermal allograft. They showed improvement in patient-reported outcomes at a mean of 22 months following surgical treatment. The authors reported 1 postoperative hematoma, which needed surgical drainage. Laskovski and Urchek⁷ suggested that this technique also can be performed endoscopically. However, performing endoscopic repairs in big massive tears could be challenging. Today, most endoscopic surgical techniques for abductors repair in the hip are derived from the treatment for the rotator cuff tear in the shoulder, with promising results of improved healing rates and functional outcomes.²²

We believe that the acellular dermal allograft provides immediate structural strength to the repair as well as a biologic environment for better tendon to bone healing. It should be considered in cases with degenerative tears, massive tears, or revision cases in which reduction of the tendon to the footprint is challenging. Previously, it has been reported that the graft remodels following implantation. Snyder et al.²³ evaluated histologically biopsy specimens obtained 3 months following rotator cuff augmentation with acellular human dermal graft. They found that the graft was incorporated with significant cellular infiltration, alignment of collagen fibers, and blood vessel ingrowth, proving that the dermal graft exhibits key biological factors of the remodeling process when used as an augmentation device in rotator cuff repair.

In conclusion, abductor repair of the hip augmented with acellular human dermal allograft provides a simple

and minimally invasive technique for patients with degenerative tears or massive or chronic tears of abductors. Future studies with a prospective cohort of patients treated with this technique will be needed to provide an objective evaluation of patient-reported outcomes following surgical repair of abductors treated augmented with dermis allograft.

References

1. Williams BS, Cohen SP. Greater trochanteric pain syndrome: A review of anatomy, diagnosis and treatment. *Anesth Analg* 2009;108:1662-1670.
2. Strauss EJ, Nho SJ, Kelly BT. Greater trochanteric pain syndrome. *Sports Med Arthrosc Rev* 2010;18:113-119.
3. Miozzari HH, Dora C, Clark JM, Notzli HP. Late repair of abductor avulsion after the transgluteal approach for hip arthroplasty. *J Arthroplasty* 2010;25:450-457.e451.
4. Lubbeke A, Kampfen S, Stern R, Hoffmeyer P. Results of surgical repair of abductor avulsion after primary total hip arthroplasty. *J Arthroplasty* 2008;23:694-698.
5. Rao BM, Kamal TT, Vafaye J, Taylor L. Surgical repair of hip abductors. A new technique using Graft Jacket allograft acellular human dermal matrix. *Int Orthop* 2012;36:2049-2053.
6. Voos JE, Shindle MK, Pruett A, Asnis PD, Kelly BT. Endoscopic repair of gluteus medius tendon tears of the hip. *Am J Sports Med* 2009;37:743-747.
7. Laskovski J, Urchek R. Endoscopic gluteus medius and minimus repair with allograft augmentation using acellular human dermis. *Arthrosc Tech* 2018;7:e225-e230.
8. Fehm MN, Huddleston JL, Burke DW, Geller JA, Malchau H. Repair of a deficient abductor mechanism

- with Achilles tendon allograft after total hip replacement. *J Bone Joint Surg Am* 2010;92:2305-2311.
9. Whiteside LA, Nayfeh T, Katerberg BJ. Gluteus maximus flap transfer for greater trochanter reconstruction in revision THA. *Clin Orthop Rel Res* 2006;453:203-210.
 10. Kohl S, Evangelopoulos DS, Siebenrock KA, Beck M. Hip abductor defect repair by means of a vastus lateralis muscle shift. *J Arthroplasty* 2012;27:625-629.
 11. Beck M, Leunig M, Ellis T, Ganz R. Advancement of the vastus lateralis muscle for the treatment of hip abductor discontinuity. *J Arthroplasty* 2004;19:476-480.
 12. Alpaugh K, Chilleli BJ, Xu S, Martin SD. Outcomes after primary open or endoscopic abductor tendon repair in the hip: A systematic review of the literature. *Arthroscopy* 2015;31:530-540.
 13. Lachiewicz PF. Abductor tendon tears of the hip: Evaluation and management. *J Am Acad Orthop Surg* 2011;19:385-391.
 14. Cvitanic O, Henzie G, Skezas N, Lyons J, Minter J. MRI diagnosis of tears of the hip abductor tendons (gluteus medius and gluteus minimus). *AJR Am J Roentgenol* 2004;182:137-143.
 15. Goutallier D, Postel JM, Bernageau J, Lavau L, Voisin MC. Fatty muscle degeneration in cuff ruptures. Pre- and postoperative evaluation by CT scan. *Clin Orthop Rel Res* 1994;78-83.
 16. Fuchs B, Weishaupt D, Zanetti M, Hodler J, Gerber C. Fatty degeneration of the muscles of the rotator cuff: Assessment by computed tomography versus magnetic resonance imaging. *J Shoulder Elbow Surg* 1999;8:599-605.
 17. Bogunovic L, Lee SX, Haro MS, et al. Application of the goutallier/fuchs rotator cuff classification to the evaluation of hip abductor tendon tears and the clinical correlation with outcome after repair. *Arthroscopy* 2015;31:2145-2151.
 18. Whiteside LA. Surgical technique: Transfer of the anterior portion of the gluteus maximus muscle for abductor deficiency of the hip. *Clin Orthop Rel Res* 2012;470:503-510.
 19. Kautzner J, Zeman P, Stancak A, Havlas V. Hip arthroscopy learning curve: A prospective single-surgeon study. *Int Orthop* 2018;42:777-782.
 20. Bucher TA, Darcy P, Ebert JR, Smith A, Janes G. Gluteal tendon repair augmented with a synthetic ligament: Surgical technique and a case series. *Hip Int* 2014;24:187-193.
 21. Ebert JR, Bucher TA, Mullan CJ, Janes GC. Clinical and functional outcomes after augmented hip abductor tendon repair. *Hip Int* 2018;28:74-83.
 22. Agrawal V. Healing rates for challenging rotator cuff tears utilizing an acellular human dermal reinforcement graft. *Int J Shoulder Surg* 2012;6:36-44.
 23. Snyder SJ, Arnoczky SP, Bond JL, Dopirak R. Histologic evaluation of a biopsy specimen obtained 3 months after rotator cuff augmentation with GraftJacket Matrix. *Arthroscopy* 2009;25:329-333.