

Technical Note

The Hip Arthroscopy Post-less Procedure Impingement (HAPPI) Technique: Achieving Distraction With Standard Hip Tables at Zero Additional Cost

Megan L. Jimenez, D.O., Masahiko Haneda, M.D., Ph.D., and
Cecilia Pascual-Garrido, M.D., Ph.D.

Abstract: Hip arthroscopy is becoming a more common treatment for femoroacetabular impingement, labral tears, and a variety of other hip pathologies. Unlike arthroscopy of the shoulder and knee, hip arthroscopy requires a significant amount of traction to gain access into the joint. Historically, traction has been achieved with the use of a perineal post. The use of a perineal post in hip arthroscopy can cause several avoidable complications such as neuropraxias (i.e., the pudendal nerve), vaginal or scrotal injuries, and perineal skin injuries. Several articles have been proposed using post-less techniques to obtain hip traction, but many of these techniques are expensive and require the purchase of new equipment. The purpose of this Technical Note is to describe a post-less technique for hip arthroscopy, the HAPPI technique (hip arthroscopy post-less procedure impingement), which is more affordable and does not require the addition of any special equipment. In addition, we will review some pearls and pitfalls, as well as advantages and disadvantages of the proposed technique.

In the past, techniques described for the arthroscopic treatment of symptomatic femoroacetabular impingement have used a perineal post to assist with traction. The perineal post applies an oblique force to the proximal femur, which helps with lateralization of the femur, thereby achieving the appropriate distraction vector. Although traction is required for hip arthroscopy, the use of a perineal post can result in several complications, including neuropraxias, vaginal or scrotal injuries, and perineal skin injuries.¹⁻³ Multiple studies have demonstrated that the majority of neuropraxias related to hip arthroscopy affect the

pudendal nerve.²⁻⁴ In a prospective study performed by Kern et al.,⁴ the incidence of nerve injury was 13% (13 of 100 patients), with 9 of these patients

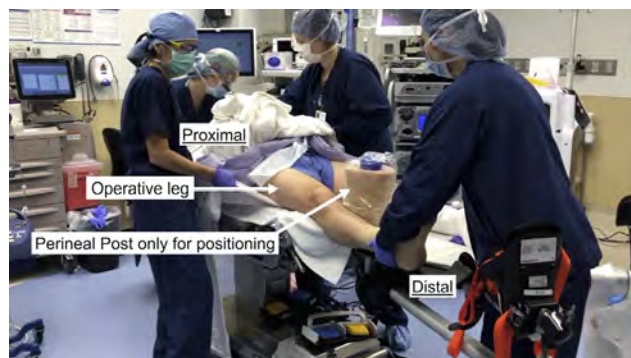

Fig 1. The patient is positioned supine and a perineal post is placed only for positioning so the patient does not fall off the bed. Once general anesthesia is performed, the patient is moved to the edge of the table on the side of the surgical hip so that the surgeon does not run into the bed with the hand when holding the camera during the surgical case. Then, both feet are padded with a 4-inch webril and only the operative foot is then wrapped in 6-inch Coban (over the webril). This wrapping prevents the foot from sliding out of the boot. In addition, the webril protects both feet. Then, the patient's body is slid down to contact the perineal post. This requires 3 assistants, one on either side of the patient and another assistant holding the legs apart.

From the Department of Orthopaedic Surgery, Washington University School of Medicine, St. Louis, Missouri, U.S.A.

The authors report that they have no conflicts of interest in the authorship and publication of this article. Full ICMJE author disclosure forms are available for this article online, as [supplementary material](#).

Received April 19, 2020; accepted July 11, 2020.

Address correspondence to Cecilia Pascual-Garrido, M.D., Ph.D., Department of Orthopaedic Surgery, Washington University School of Medicine, 660 South Euclid Ave., Campus Box 8233, St. Louis, MO 63110. E-mail: cpascualgarrido@wustl.edu

© 2020 by the Arthroscopy Association of North America. Published by Elsevier. This is an open access article under the CC BY-NC-ND license (<http://creativecommons.org/licenses/by-nc-nd/4.0/>).

2212-6287/20739

<https://doi.org/10.1016/j.eats.2020.07.012>

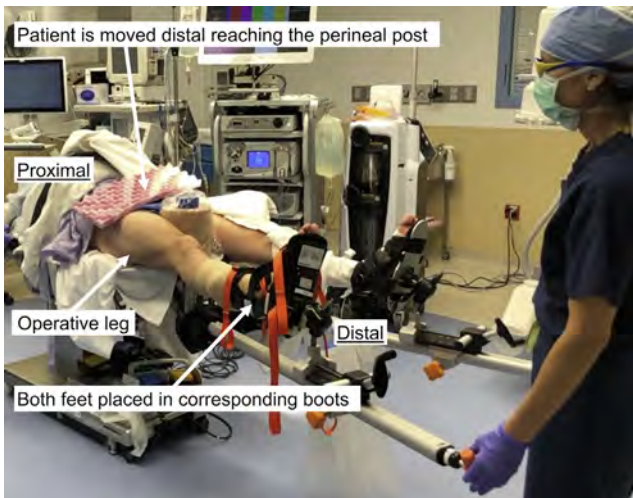


Fig 2. The operative knee is flexed and placed into the Active Heel Traction Boot (Smith & Nephew), whereas the nonoperative knee is flexed and placed in a Well Leg Holder with Leather Boot (Smith & Nephew). It is crucial for the heel of the operative leg to be seated all the way in the Active Heel Traction as previously described. The boot and the straps are fully tightened several times. The post is used at this point only to adjust patient's positioning on the table. After both feet are fixed within each boot, both knees are loosely extended.

presenting with a pudendal compression-type traction neuropraxia.

Post-less techniques have been described more recently with the aim to reduce complications related to the use of a post. The main disadvantages of these systems include the high cost and varying patient positioning.^{1,5-7} Some techniques require the patient to

remain in Trendelenburg, whereas others limits anesthesia an adequate access to the upper extremities.

This Technical Note presents a hip arthroscopy post-less procedure impingement (HAPPI) technique that obtains post-less traction that can be used with standard hip distraction tables, thereby reducing the substantial costs related to post-less tables and pads. In addition, the patient does not need to be in the Trendelenburg position to maintain traction; thus, the patient is in a level position before procedure starts. We believe this technique allows the surgeon to continue using their bed of choice with zero additional cost.

Technique

Patient Positioning

All current hip distraction beds can be modified for the HAPPI technique. At our institution, the patient is placed supine on the current hip distraction table, Hip Positioning System (Smith & Nephew, Andover, MA). General anesthesia is performed and, once the patient is asleep, the perineal post is positioned between the patient's legs. The post is only required during positioning and is used for safety reasons. It allows for the patient to be positioned in the ideal location on the bed without the concern for the patient falling off a very narrow platform. Both the patient's feet are first padded with 4-inch webril and the operative foot is then wrapped in a 6-inch Coban (Fig 1). The operative knee is flexed and placed into the Active Heel Traction Boot (Smith & Nephew), while the nonoperative knee is flexed and placed in a Well Leg Holder with Leather Boot (Smith & Nephew). It is crucial for the heel of the operative leg to be seated all the way in the Active Heel Traction as

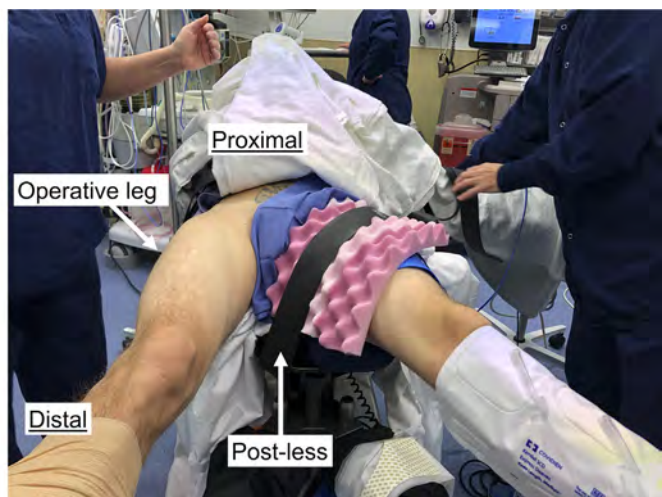
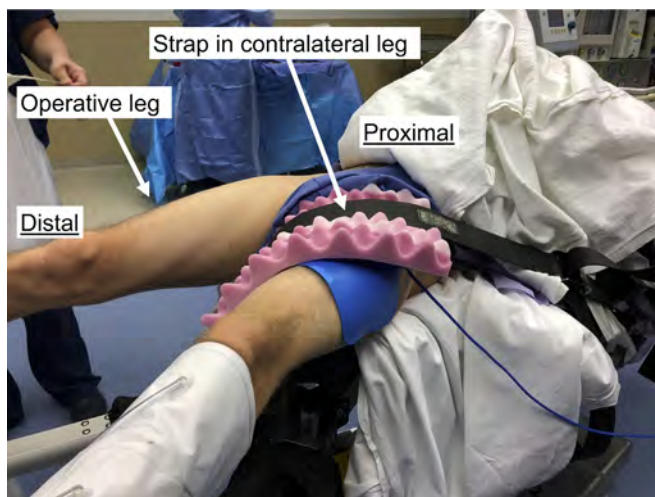

Fig 3. The post is removed, and a full piece of pink egg crate is placed on the nonoperative leg. The egg crate should drape proximally from the anterior thigh to the medial thigh. The safety strap is draped over the pink egg crate with the metal portion of the strap directly on the pink egg crate. The strap is then brought between the patient's legs and under the bed, then through the opposite side of the bed to keep it from sliding (similar to how the safety strap is used in a normal supine case). Finally, the strap is brought over top of the pink egg crate, from lateral to medial, and tightened.

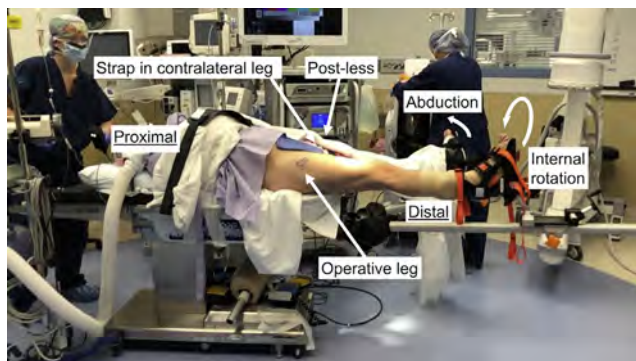


Fig 4. Patient positioning before Trendelenburg. The post has been removed and the strap has been positioned on the contralateral leg. The operative leg is internally rotated so that the patella is parallel with the floor. The nonoperative leg is abducted enough for radiographs to have adequate space.

previously described (Smith & Nephew). The boot and the straps are fully tightened, and both knees are loosely extended (Fig 2).

Attention is then paid to the upper extremities. The nonoperative side arm is extended out onto a well-padded arm board. The operative side arm is placed across the patient's chest with the elbow flexed to 90° over blankets and secured with 2-inch silk tape.

Removal of the Post and Securing of the Contralateral Leg with a Strap

At this point, a safety strap (AliMed, Dedham, MA) and pink egg crate (Cardinal Health, Dublin, OH) are used for countertraction and the post is removed. The pink egg crate is placed proximally on the nonoperative leg directly over the anterior and medial thigh to protect the skin. Then, the safety strap is placed over the pink egg crate and wrapped under and around the bed. The metal piece of the safety strap remains on the pink egg crate and the strap is tightened. Once both extremities

are secured in their boots and the safety strap is in position, the contralateral leg is abducted about 25 to 30° and placed in minimal traction to balance the traction force that will be placed on the operative leg (Fig 3).

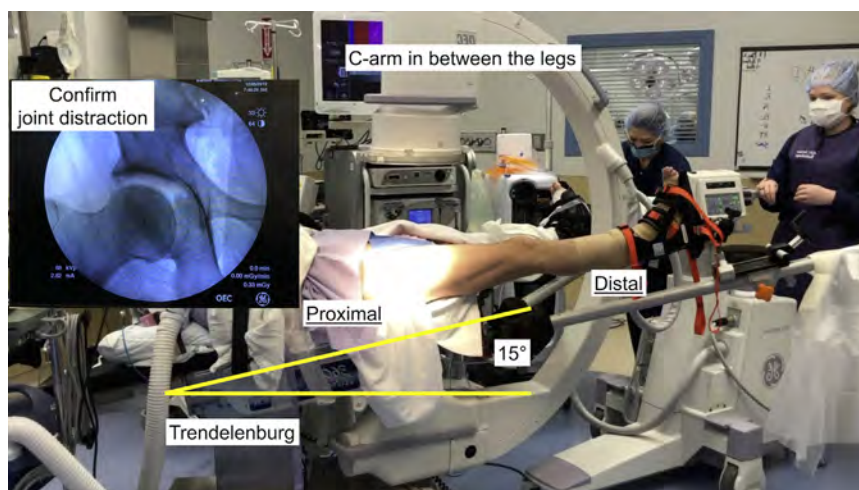
Obtaining Traction Preoperatively

Before prepping and draping, the surgeon should confirm the ability to obtain appropriate traction to the hip joint with the HAPPI technique. The bed is placed in about 15° of Trendelenburg. First, gross traction is performed on the contralateral leg. Second, the operative leg is adducted about 20° and in-line, gross traction is performed. Third, about 5 rounds of fine traction are placed on the operative lower extremity. A radiograph is performed to assess how much traction has been obtained at this point. Five-round intervals of fine traction are continued with radiographs taken at each 5-round interval until adequate joint space is obtained. While increasing the traction, continually monitor the heel to make sure it remains seated in the traction boot. Begin to adduct the lower extremity with a steady downward pressure on the leg holder, as the hip traction table operative leg tends to ride in an upwards direction with increasing amounts of traction. Once appropriate traction is confirmed preoperatively, the traction on the bilateral extremities is completely removed, to prep and drape the patient, while the patient remains in Trendelenburg. Compared with other post-less techniques, a Trendelenburg position is not required for surgery and it is only used to obtain initial distraction of the hip joint (Figs 4 and 5). If, for any reason, the surgeon is unable to obtain sufficient traction without a post, the HAPPI technique can be aborted and a post can be easily added before or during surgery.

Initiation of Hip Arthroscopy (With Video Illustration)

The operative lower extremity is prepped with chlorhexidine while the surgeon and assistant scrub

Fig 5. Before draping, it is important to confirm that traction is obtainable. The C-arm is brought in between the patient's lower extremities. The bed is positioned in 15° of Trendelenburg. Gross traction is first performed on the contralateral leg followed by gross traction on the operative leg. The fluoroscopy confirms that joint distraction is successfully obtained before draping.



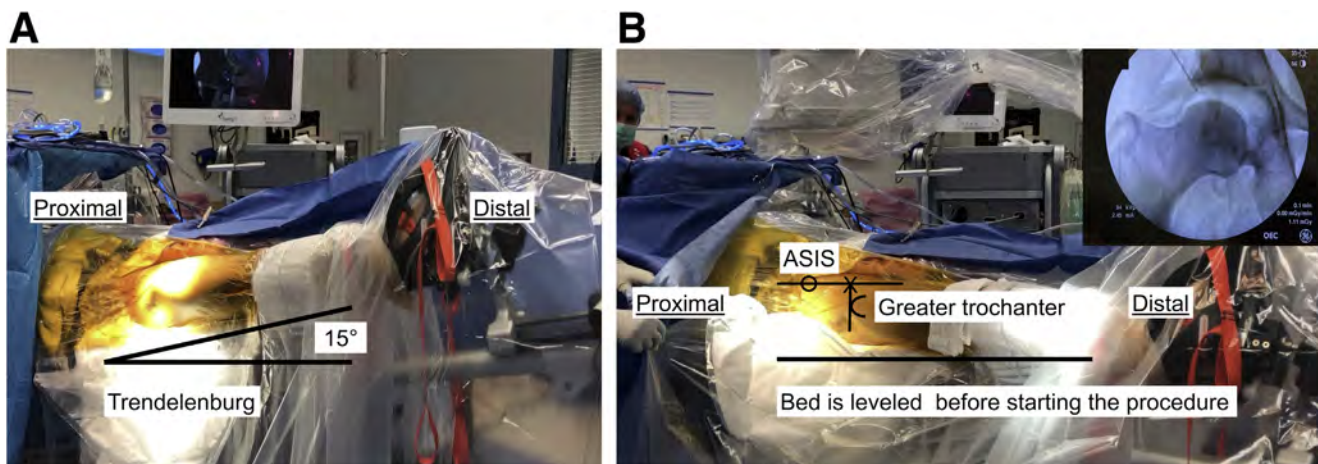


Fig 6. (A) The bed is leveled out after appropriate traction is obtained and arthroscopy is started with conventional portals. (B) The X shows the location where the 17-gauge needle should be inserted to vent the joint. This is the intersection of a line that goes through the anterior superior iliac spine (ASIS) and the tip of the greater trochanter, similar to the true anterior portal location.

into surgery. A sterile shower curtain drape is used. The patient is still in the Trendelenburg position at this time (Fig 6A). A 17-gauge spinal needle, filled with air, is used to vent the joint. For needle placement, 1 line is drawn from the anterior superior iliac spine straight down the leg and another is drawn from the tip of the greater trochanter and carried out medially. This needle is placed at the intersection of these 2 lines (Fig 6B). The circulating nurse pulls gross traction on the contralateral leg, followed by gross traction on the operative leg, as described previously. While the operative leg is pulled with gross traction, approximately 20 to 25 mL of air is inserted into the hip joint through the 17-gauge

needle to help break the seal. With the use of fluoroscopy and fine traction, traction is slowly increased until there is concentric clear space in the joint both in the superior-inferior direction as well as medially. Before making any portals, it is crucial that the bed is leveled back to neutral to remove Trendelenburg. The hip will remain distracted once Trendelenburg is removed. At this point, hip arthroscopy may begin with creation of the corresponding portals (Video 1). Pearls and pitfalls of this technique are shown in Table 1, advantages and disadvantages are shown in Table 2, and step-by-step techniques are shown in Table 3.

Discussion

Although a perineal post is still frequently used for hip arthroscopy, various techniques have been described without the use of a post.^{1,5-7} In this Technical Note, we describe a post-less technique for hip arthroscopy using the Hip Positioning System

Table 1. Pearls and Pitfalls

Pearls	Pitfalls
Use the post initially to position the patient appropriately on the traction table.	Do not remove the post too early.
Before strapping the contralateral leg, remove the post.	The operative leg tends to ride up during traction. This can be resisted with downward pressure on the leg holder.
Table should be positioned in 15° of Trendelenburg. More traction can be used if needed.	The foot can easily slide out of the boot during traction. If this happens, undue bilateral traction and redo the foot wrap.
Obtain traction while venting the joint.	
Use the C-arm to confirm adequate traction.	It can be challenging to obtain a good radiograph while the patient is in Trendelenburg. The bed can sometimes obscure the radiograph. If this happens, rainbow the C-arm around 10°.
Bring the bed back to neutral (from 15° of Trendelenburg) after obtaining traction.	If you lose traction, you can restore it by putting the patient back into Trendelenburg.

Table 2. Advantage and Disadvantages

Advantages	Disadvantages
Decreased risk of pudendal nerve injury.	Can sometimes be difficult to break the seal. Using an air arthrogram simultaneously as traction is pulled can aid with breaking the seal.
Decreased risk of skin, scrotal, and vaginal injuries.	Requires the initial use of Trendelenburg. Trendelenburg may be removed once appropriate traction is achieved.
No additional costs.	Requires the use of additional steps in the patient setup preoperatively. Whereas the traditional beds allow you to insert a post, this technique requires the use of a pink egg crate and a safety strap.

Table 3. Step-by-Step Technique

Step	Details
1. Patient positioning	The patient is positioned on the surgeon's standard hip arthroscopy table. Post is used only during positioning. Feet are padded and placed in their boots. Upper extremities are positioned appropriately (Figs 1 and 2).
2. Removal of post and placement of safety strap.	Safety strap and soft-tissue pad are placed on the contralateral thigh and the post is removed (Fig 3).
3. Obtain traction preoperatively.	The bed is placed in 15° of Trendelenburg. Place gross traction on the contralateral leg followed by gross traction, then fine traction of the operative leg. Obtain fluoroscopy periodically to assess traction. Once adequate traction is confirmed, remove bilateral traction completely (Figs 4 and 5).
4. Initiation of hip arthroscopy	The operative leg is prepped and draped. A 17-gauge needle is placed in the location of the anterior portal to help break the seal. As traction is pulled 20 to 25 mL of air is inserted into the needle. Once traction is achieved, remove Trendelenburg and level the bed out (Fig 6).

(Smith & Nephew), although the technique can be used with any bed. This technique only requires a safety strap (AliMed) and pink egg crate (Cardinal Health) or any type of soft-tissue padding. In addition, the Trendelenburg position is only required for initial hip distraction and is completely removed before beginning hip arthroscopy.

The perineal post used in hip arthroscopy can cause several complications, with the most common being neuropraxias.¹⁻³ A recent systematic review showed that pudendal nerve injuries occur at a rate of about 1.8%, although all of these resolved by 3 months postoperatively.² The main advantage of using post-less hip arthroscopy is the decreased risk of pudendal nerve injury, along with a decreased risk for scrotal or vaginal injuries and perineal soft-tissue injuries. In addition, our technique can be performed at no additional cost to the surgeon or hospital. The regular safety strap (AliMed) used in this technique is a regular strap that all operating rooms have available to secure patients. We propose using the pink egg crate (Cardinal Health) to protect the soft tissue; however, the surgeon can use any type of soft tissue padding.

The biggest limitation of the post-less technique is failure to obtain adequate traction without the post. The most challenging patients are those with a low body mass index, because of low countertraction force, and those patients with a severe pincer deformity. In these situations, adding more Trendelenburg (20-25°) initially can be helpful. We also use an air arthrogram via the anterior portal, which is performed simultaneously with leg traction. This is performed by placing 25-mL syringe through a 17-gauge needle, without the creation of an actual portal. If these adjustments still don't provide adequate traction, the post-less technique may be aborted by replacing the pink egg crate and safety strap with a post.

In conclusion, post-less surgery has become a popular method of performing hip arthroscopy. There are

various techniques for achieving traction without a post, but the majority require special beds and special equipment. The HAPPI technique can be performed with any hip traction table, at zero additional cost and with the patient leveled before procedure starts.

Acknowledgments

The authors thank Linda S Daake, R.N., and Susan M Earley, R.N., B.S.N., for helping develop and optimizing the technique.

References

1. Salas AP, Mazek J, Araujo-Reyes D, Gonzalez-Campos M, Castillo-Trevizo A, Garcia JM. The Tutankhamun technique in hip arthroscopy. *Arthrosc Tech* 2018;7:e1167-e1171.
2. Habib A, Haldane CE, Ekhtiari S, et al. Pudendal nerve injury is a relatively common but transient complication of hip arthroscopy. *Knee Surg Sports Traumatol Arthrosc* 2018;26:969-975.
3. Nakano N, Khanduja V. Complications in hip arthroscopy. *Muscles Ligaments Tendons J* 2016;6:402-409.
4. Kern MJ, Murray RS, Sherman TI, Postma WF. Incidence of nerve injury after hip arthroscopy. *J Am Acad Orthop Surg* 2018;26:773-778.
5. Welton KL, Garabekyan T, Kraeutler MJ, et al. Effects of hip arthroscopy without a perineal post on venous blood flow, muscle damage, peripheral nerve conduction, and perineal injury: A prospective study. *Am J Sports Med* 2019;47:1931-1938.
6. Kollmorgen RC, Ellis T, Lewis BD, Harris JD. Achieving post-free distraction in hip arthroscopy with a pink pad patient positioning device using standard hip distraction tables. *Arthrosc Tech* 2019;8:e363-e368.
7. Mei-Dan O, Kraeutler MJ, Garabekyan T, Goodrich JA, Young DA. Hip distraction without a perineal post: A prospective study of 1000 hip arthroscopy cases. *Am J Sports Med* 2018;46:632-641.