

## Technical Note

---

# Inside Out: A Novel Labral Repair and Advancement Technique

Omer Mei-Dan, M.D., Cecilia Pascual-Garrido, M.D., Jonathan A. Kark, and Mark O. McConkey, M.D.

---

**Abstract:** Labral tears are a significant cause of hip pain and are currently the most common indication for hip arthroscopy. Compared with labral debridement, labral repair has significantly better outcomes in terms of both daily activities and athletic pursuits in the setting of femoral acetabular impingement. The techniques described in the literature all use anchor placement on the capsular aspect of the acetabular rim, which can be difficult especially anteriorly, where the rim is very thin, and has the potential for significant complications. Anchor breakage, anchor slippage into the surrounding (capsular side) soft tissue, and penetration of the cartilage surface are among the most common complications. We describe an intra-articular anchor placement technique for labral repair from inside out. This technique, because of the location of the anchor and direction of suture pull, can assist in labral advancement in cases in which the native labrum fails to create a seal because of its location away from the femoral head.

---

The incidence of acetabular labral tears has been increasing as techniques to diagnose them have advanced.<sup>1</sup> Damage to the labrum is responsible for a marked reduction in its function, resulting in greater load forces on the labrum itself,<sup>2</sup> as well as increased resistance to rotation,<sup>3</sup> and can potentiate possible damage to the articular surface, which may be a predisposing factor for osteoarthritis.<sup>4</sup> A suture anchor is most commonly used for reattaching the torn labrum to the acetabular rim.<sup>5</sup> Previously described repair techniques all use anchor placement on the capsular aspect of the acetabular rim and labrum,<sup>5</sup> a position that is not always ideal. A shallow dysplastic hip, the drilling trajectory, the narrow width of the acetabular rim, or some specific anatomic variations may generate difficulty during anchor placement. Furthermore, anatomic anomalies do exist in the acetabular labrum, in which

the native labrum does not create an adequate suction seal with the femoral head, reducing even distribution of cushioning synovial fluid and increasing the forces within the joint. In anatomic cases such as these, the superior deviation of the labrum would only be worsened by the direction of pull from sutures coming out of an anchor placed behind the labrum, displacing the labrum from the correct anatomic position that much further.

We describe an intra-articular anchor placement technique that provides a means to repair a torn labrum when more standard approaches are less ideal. This technique can also assist in labral advancement (pulling the labrum toward the femoral head to create a more functional seal) when the native labrum fails to create a proper seal because of its location away from the femoral head.

---

*From the Sports Medicine and Hip Preservation Service, Department of Orthopedics (O.M.-D., C.P.-G.), and School of Medicine (J.A.K.), University of Colorado, Aurora, Colorado, U.S.A.; and Pacific Orthopaedics and Sports Medicine (M.O.M.), North Vancouver, British Columbia, Canada.*

*The authors report that they have no conflicts of interest in the authorship and publication of this article.*

*Received October 2, 2013; accepted November 7, 2013.*

*Address correspondence to Omer Mei-Dan, M.D., Sports Medicine and Hip Preservation Service, Department of Orthopedics, University of Colorado School of Medicine, 12631 E 17th Ave, Mailstop B202, Academic Office 1, Room 4602, Aurora, CO 80045, U.S.A. E-mail: [Omer.meidan@ucdenver.edu](mailto:Omer.meidan@ucdenver.edu)*

*© 2014 by the Arthroscopy Association of North America*

*2212-6287/13707/\$36.00*

*<http://dx.doi.org/10.1016/j.eats.2013.11.002>*

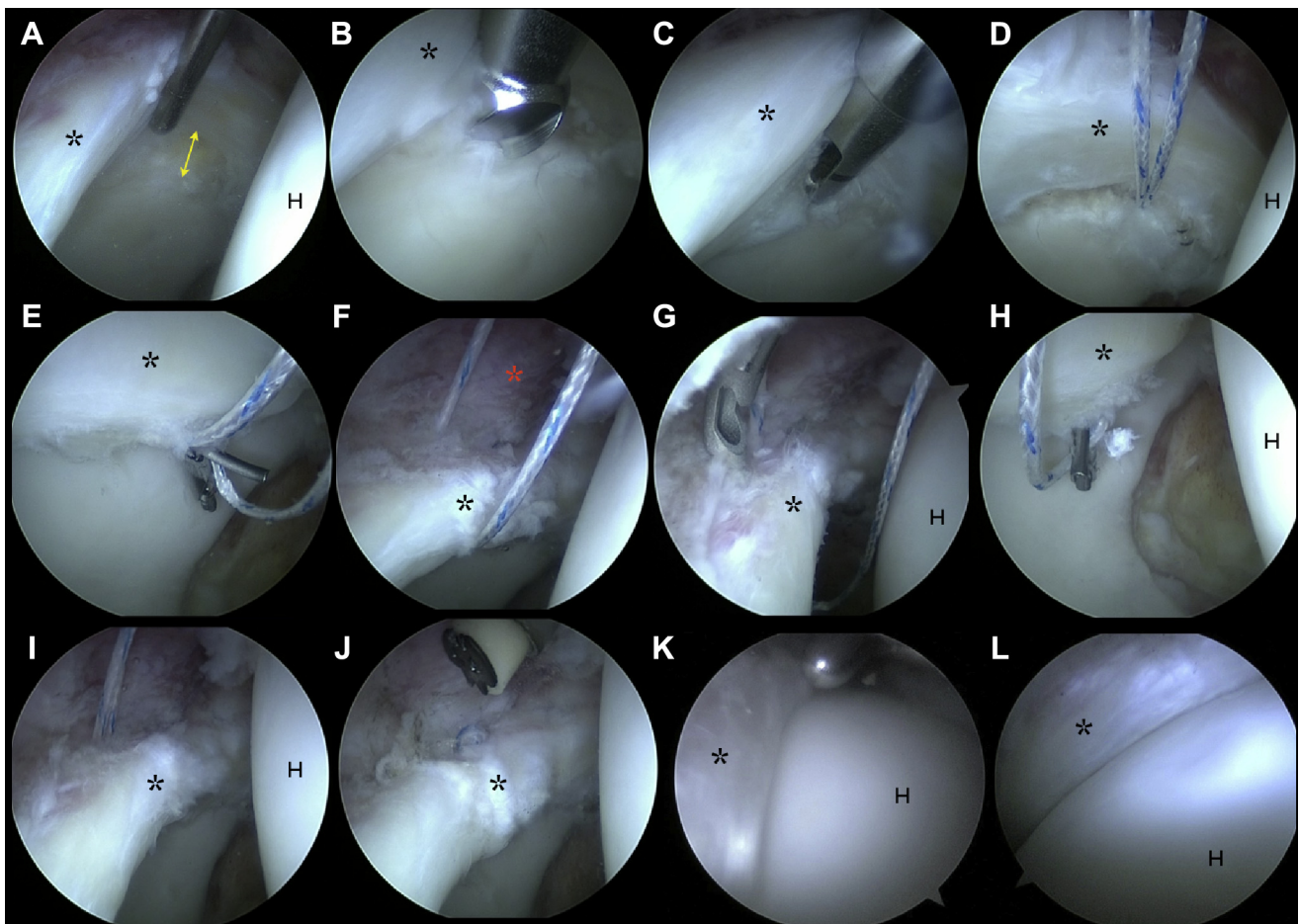
## Surgical Procedure

The patient is placed supine on a surgical table, and the feet are well padded and placed into traction boots as described by Mei-Dan et al.<sup>6</sup> After sterile preparation and draping, the patient is placed in 10° to 15° of Trendelenburg position, traction is wound on, and a spinal needle is used to break the suction seal of the hip. When adequate joint distraction is obtained, a peritrochanteric portal is made with the aid of fluoroscopy and the arthroscope is introduced into the hip. An anterior portal is then made under direct vision, and a capsulotomy is made, allowing diagnostic arthroscopy to take place.

When a labral tear is found, it is examined to determine the most appropriate repair technique. If the patient is known to have dysplasia or does not have a pincer lesion, he or she is a good candidate for the “inside-out” technique. Unlike the non-dysplastic hip, in which bone on the capsular side of the labrum can be liberally taken down with an arthroscopic burr (i.e., pincer deformity), judicious rim trimming must be used in order not to worsen the pathologic undercoverage found in a dysplastic hip.

The labrum is lifted from inferior to superior with a fine rasp or shaver (Double Bite; Stryker, Kalamazoo, MI), and gentle burring is completed with a 4-mm unhooded burr (Stryker) at the site at which the anchor will be placed to allow for some bleeding to facilitate revascularization for healing (Fig 1). Standard anchor drilling techniques are used; however, the anchor placement is

from inferior to superior, from the articular side of the joint, at the chondrolabral junction (Video 1). This ensures ample bone in which the anchor can take hold. A guide is placed against the acetabulum at the desired location, and a drill hole for the anchor is made. The anchor (Pivot Nanotack; Pivot Medical, Sunnyvale, CA) is tapped into place. Once the anchor has been secured, a labral base repair, or a repair with stitches around the labrum, can be performed. To complete the labral base repair, both suture limbs are retrieved through the labrum, in a mattress fashion, to the capsular side of the labrum with an arthroscopic suture passer (Pivot Nanopass; Pivot Medical). Arthroscopic knot-tying techniques are used to secure the labral repair. For the classic repair method, only 1 suture limb is retrieved to the capsular side of the labrum and the knot is tied on this side by use of both suture limbs (Fig 1).



**Fig 1.** The inside-out technique is shown in a right hip with the patient in the supine position, the camera in the peritrochanteric portal, and the instruments in the anterior portal. (A) A probe is used to show the labral tear. (B) A burr is used inferior to the labrum to roughen the contact point and improve healing potential. (C) The guide is placed. (D) The anchor has been placed inferior to the labrum, well away from the capsule. (E) The suture passer is used to retrieve 1 limb. (F) The first limb of the suture is passed through the base of the labrum. (G) The suture retriever is again being passed through the labrum. (H) The suture retriever is grasping the second limb of suture. (I) Both limbs have been passed in a mattress fashion around the labrum. (J) A knot has been tied on the capsular side to secure the labrum. (K) The traction has been let down, showing the labrum well apposed to the femoral head. (L) The labral seal is shown with another camera angle. The black asterisks indicate the labrum, the red asterisk indicates the capsule, and the arrow indicates the labral tear. (H, femoral head.)

To perform a labral advancement, the anchor is placed in the same fashion, but this is performed after the labrum is freed from its native attachment away from the chondrolabral junction. Once the labrum can be mobilized freely with a probe, it will be brought closer to the chondrolabral junction by use of the anchor suture limbs. Both classic repair and labral base techniques can be used, depending on tissue size and characteristics (Fig 2). A small labrum necessitates a classic around-the-labrum repair, whereas a large labrum can be stabilized well with a labral base repair, without the sutures cutting through the tissue.

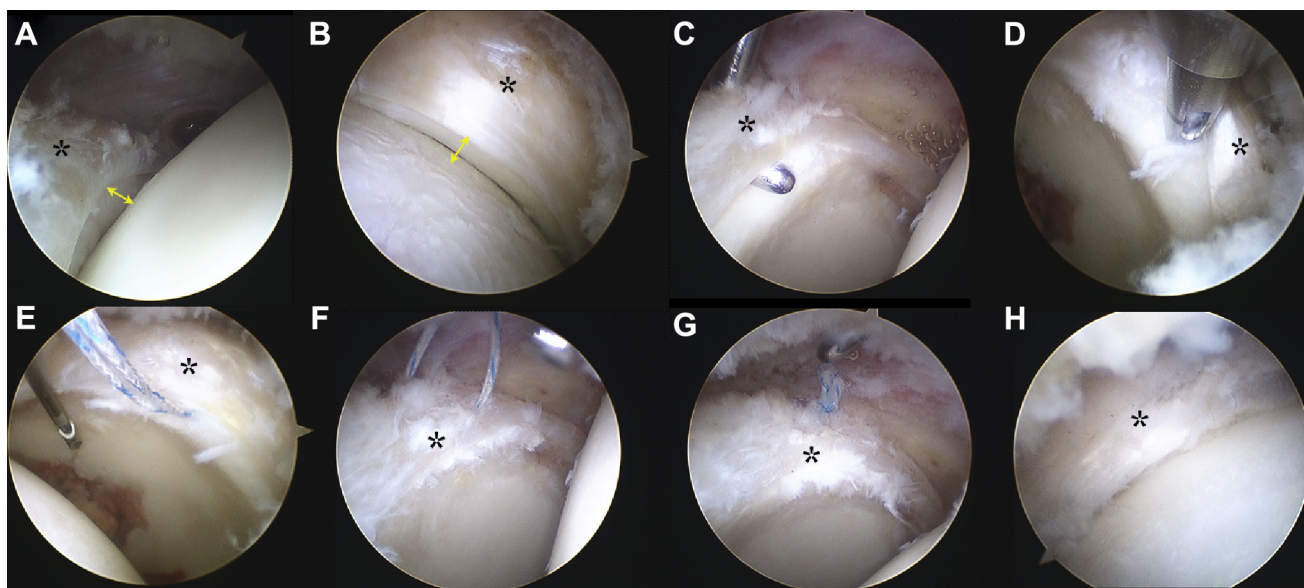
The remainder of the surgical procedure continues as with any standard hip arthroscopy, with release of the hip distraction and evaluation of the peripheral compartment arthroscopically to ensure that a proper seal is created around the femoral head by the repaired labrum. Any osteoplasty necessary is undertaken, and impingement is dynamically assessed. We repair the capsule if possible at the completion of the procedure.

### Discussion

Current methods used to treat labral tears may be limited in their efficacy in some patients with severe dysplasia of the hip with limited coverage of the femoral head, as well as in patients whose acetabulum is not amenable to conventional acetabular rim trimming before conventional capsular-sided suture anchor

placement. This can be because of socket morphology, the drilling trajectory, and the narrow width of the acetabular rim. Furthermore, individuals with a poor labral seal as a result of proximally positioned labral attachments are not ideal candidates for conventional labral repair because the vector of forces pulling on the suture can worsen the superior separation of the labrum from the femoral head. In the presented technique the intra-articular placement of the suture anchor allows the surgeon to place the anchor in bone with ample substance while the anchor position allows the forces to pull the labrum inferiorly, instead of superiorly, helping to ensure a good seal and encouraging a more natural anatomic function (Table 1). Haene et al.<sup>7</sup> showed that 46% of patients with a torn labrum had underlying dysplasia of the hip, and in patients with a symptomatic dysplastic hip, labral pathology is present 90% of the time.<sup>2</sup> As such, it is imperative that the orthopaedic surgeon recognize the presence of these pathologies and is prepared for alternative techniques when the dysplastic acetabular anatomy is not amenable to capsular sided anchor placement for labral reattachment.

Several authors have described the appropriate range of angles in which the anchor can be placed superiorly to provide the greatest hold.<sup>8,9</sup> However, in some cases of dysplasia and narrow rim width, and especially far anterior on the acetabular rim, the amount of bone



**Fig 2.** The inside-out technique is shown in a right hip with the patient in the supine position and the camera in the peritrochanteric portal so that the labrum can be advanced to the edge of the acetabulum. (A) The labrum is shown sitting superior to the edge of the acetabulum, failing to form an appropriate seal against the femoral head. (B) A suction seal is lacking with the labrum sitting away from the femoral head. (C) The labrum is freed from its current rim attachment. (D) The drill guide is placed in an inside-out position. (E) The anchor has been placed. (F) A limb has been passed through the base of the labrum. (G) The labrum is repaired to the edge of the acetabulum by use of the inside-out technique with the anchor placed on the acetabular side of the labrum instead of the capsular side. (H) A suction seal is now formed between the femoral head and the acetabular labrum. The asterisks indicate the labrum, and the arrows indicate the labral tear.

**Table 1.** Technical Pearls for Labral Repair With Inside-Out Technique

- 
- Small-diameter anchors (1.4 to 1.6 mm) are used to avoid damaging the chondrolabral junction.
  - The technique is optimal for patients with hip dysplasia, a narrow acetabular rim, far anterior labral tears, and labra with a compromised suction seal because of naturally everted labrum.
  - Proper orientation of the suture anchor should be ensured (the drilling trajectory should always be away from the cartilage surface, under direct vision).
  - In far anterior tears a slotted cannula can be used to guide the suture passer to the required area to protect it from bending or breaking because of the awkward working angle.
  - The suture limbs are best retrieved with a small-diameter suture passer.
  - The surgeon must ensure that there is enough labral tissue between the entry points of the suture passer so that a secure arthroscopic knot can be tied without cutting through the tissue.
- 

needed for significant hold is impossible to achieve, and in such cases an articular sided placement, or an inside-out approach, may be the most viable option.

In cases of anatomic variations, in which the labrum does not create an adequate suction seal because of superior deviation of the labrum, with or without a labral tear, the direction of pull from conventional anchor placement sutures would be unfavorable. Conventional repair could worsen the labrum anatomy, pulling it further from the correct anatomic position, thereby worsening the pathoanatomy. The described technique can restore the physiological suction seal while maintaining the native labrum. In addition, when one is performing a labral repair from the articular surface, the need to separate the capsule from the labrum, as well as to trim bone on the capsular side, is eliminated. Philippon et al.<sup>10</sup> established that labral adhesions were the major factor necessitating revision hip arthroscopy. By implementing this method of repair, the risk of adhesions developing is minimized, thereby decreasing the need for potential revisions in the future.<sup>10</sup>

As with any surgical procedure, there are potential risks and limitations to the inside-out technique. Because it is different from the common anchor placement technique, above the labrum, the angle created by the drill guide is slightly different and care must be taken to avoid penetration into the articular cartilage with the anchor. The technique is safe and reproducible overall but requires practice and attention to be performed safely and effectively.

Labral pathology is a significant contributor to the development of hip pain. In patients with both dysplastic hips and labral damage, we believe that previously

described techniques may not adequately address problems unique to this population. There is less bone available to trim for the repair, because of an already shallow socket, and popular methods have used anchor placements superior to the labrum, which—for multiple reasons—is not always feasible. In addition, for patients with anatomic variability, in whom the labrum does not create adequate suction within the joint itself, this method can also restore normal functionality by restoring normal anatomic positioning of the labrum. Lastly, the most common complications necessitating arthroscopic revision, namely adhesions, are minimized because the capsule is left intact. The intra-articular anchor placement described in this article provides an alternative method for anchor placement, using standard approaches and operative techniques, allowing for easier repair in previously difficult-to-treat operative patients.

## References

1. Philippon MJ, Schroder e Souza BG, Briggs KK. Labrum: Resection, repair and reconstruction sports medicine and arthroscopy review. *Sports Med Arthrosc* 2010;18:76-82.
2. Hartig-Andreasen C, Soballe K, Troelsen A. The role of the acetabular labrum in hip dysplasia. A literature overview. *Acta Orthop* 2013;84:60-64.
3. Song Y, Ito H, Kourtis L, Safran MR, Carter DR, Giori NJ. Articular cartilage friction increases in hip joints after the removal of acetabular labrum. *J Biomech* 2012;45:524-530.
4. Seldes RM, Tan V, Hunt J, Katz M, Winiarsky R, Fitzgerald RH Jr. Anatomy, histologic features, and vascularity of the adult acetabular labrum. *Clin Orthop Relat Res* 2001;(382):232-240.
5. Kelly BT, Weiland DE, Schenker ML, Philippon MJ. Arthroscopic labral repair in the hip: Surgical technique and review of the literature. *Arthroscopy* 2005;21:1496-1504.
6. Mei-Dan O, McConkey MO, Young DA. Hip arthroscopy distraction without the use of a perineal post: Prospective study. *Orthopedics* 2013;36:e1-e5.
7. Haene RA, Bradley M, Villar RN. Hip dysplasia and the torn acetabular labrum: An inexact relationship. *J Bone Joint Surg Br* 2007;89:1289-1292.
8. Lertwanich P, Ejnisman L, Torry MR, Giphart JE, Philippon MJ. Defining a safety margin for labral suture anchor insertion using the acetabular rim angle. *Am J Sports Med* 2011;39(suppl):111S-116S.
9. Hernandez JD, McGrath BE. Safe angle for suture anchor insertion during acetabular labral repair. *Arthroscopy* 2008;24:1390-1394.
10. Philippon MJ, Schenker ML, Briggs KK, Kuppersmith DA, Maxwell RB, Stubbs AJ. Revision hip arthroscopy. *Am J Sports Med* 2007;35:1918-1921.