



ELSEVIER

Contents lists available at ScienceDirect

The Journal of Arthroplasty

journal homepage: www.arthroplastyjournal.org

Original Article

Evidence for the Use of Cell-Based Therapy for the Treatment of Osteonecrosis of the Femoral Head: A Systematic Review of the Literature

Nicolas S. Piuizzi, MD ^{a, b, c}, Jorge Chahla, MD ^d, John B. Schrock, BS ^e,
Robert F. LaPrade, MD, PhD ^{c, f}, Cecilia Pascual-Garrido, MD ^e, Michael A. Mont, MD ^a,
George F. Muschler, MD ^{a, b, *}

^a Department of Orthopaedics, Cleveland Clinic, Cleveland, Ohio

^b Department of Biomedical Engineering, Cleveland Clinic, Cleveland, Ohio

^c Instituto Universitario del Hospital Italiano de Buenos Aires, Ciudad Autónoma de Buenos Aires, Argentina

^d Department of Biomedical Engineering, Steadman Philippon Research Institute, Vail, Colorado

^e Department of Orthopaedics, University of Colorado, Aurora, Colorado

^f The Steadman Clinic, Vail, Colorado

ARTICLE INFO

Article history:

Received 27 October 2016

Received in revised form

23 November 2016

Accepted 28 December 2016

Available online xxx

Level of Evidence:

III

Systematic review

Keywords:

osteonecrosis of the femoral head

cell therapy

hip preservation

systematic review

stem cells

cell-based therapy

ABSTRACT

Background: Cell-therapy has been promoted among the therapeutic arsenal that can aid in bone formation and remodeling, in early stages of osteonecrosis of the femoral head (ONFH). The purpose of this systematic review was to assess the evidence supporting the (1) clinical efficacy; (2) structural modifying effect, as evaluated radiographically; (3) revision rates; and (4) safety of cell-therapy for the treatment of ONFH.

Methods: A systematic review was performed including studies with a level-of-evidence of III or higher. A total of 1483 articles were screened. Eleven studies met the criteria for inclusion in this review (level-of-evidence: 6 level-I, 1 level-II, and 4 level-III), including 683 cases of ONFH.

Results: All 10 studies that reported patient-reported outcomes showed improved outcomes in the cell-therapy groups compared with the control group. Overall, 24.5% (93/380 hips) that received cell-therapy showed radiographic progression compared with 40% (98/245 hips) in the control group. Nine of 10 studies that reported failure rates showed a lower total hip arthroplasty conversion rate in the cell-therapy group 16% (62/380 hips) compared with the control group 21% (52/252 hips). There was a low complication rate (<3%) with no major adverse effects.

Conclusion: Cell-therapies for the treatment of ONFH have been reported to be safe and suggest improved clinical outcomes with lower disease progression rate. However, there was substantial heterogeneity in the included studies, and in the cell-based therapies used. Specific clinical indications and cell-therapy standardization are required because studies varied widely with respect to cell sourcing, cell characterization, adjuvant therapies, and assessment of outcomes.

© 2017 Elsevier Inc. All rights reserved.

Osteonecrosis of the femoral head (ONFH) accounts for approximately 8%-12% of all total hip arthroplasty (THA) cases in the United States [1]. It is characterized by compromised subchondral microcirculation, necrosis of the bone, and microfracture

accumulation without sustained remodeling [2,3]. Because ONFH most frequently occurs in young patients, and progression to symptoms or collapse occurs in approximate 60% of asymptomatic patients, [3,4] joint preserving techniques should be considered in early precollapse stages, to avoid or delay the cost and risk of THA, especially when patients are caught in early (precollapse) stages [5].

Core decompression (CD) is a surgical technique for joint preservation in early ONFH, typically performed by drilling to remove a cylindrical core through the femoral neck deep into the osteonecrotic lesion [1,6]. This is believed to reduce the pressure in the femoral head and open an unobstructed path through which potential

One or more of the authors of this paper have disclosed potential or pertinent conflicts of interest, which may include receipt of payment, either direct or indirect, institutional support, or association with an entity in the biomedical field which may be perceived to have potential conflict of interest with this work. For full disclosure statements refer to <http://dx.doi.org/10.1016/j.arth.2016.12.049>.

* Reprint requests: George F. Muschler, MD, Department of Orthopaedic Surgery and Biomedical Engineering, Cleveland Clinic, 9500 Euclid Avenue, Cleveland, OH 44195.

<http://dx.doi.org/10.1016/j.arth.2016.12.049>

0883-5403/© 2017 Elsevier Inc. All rights reserved.

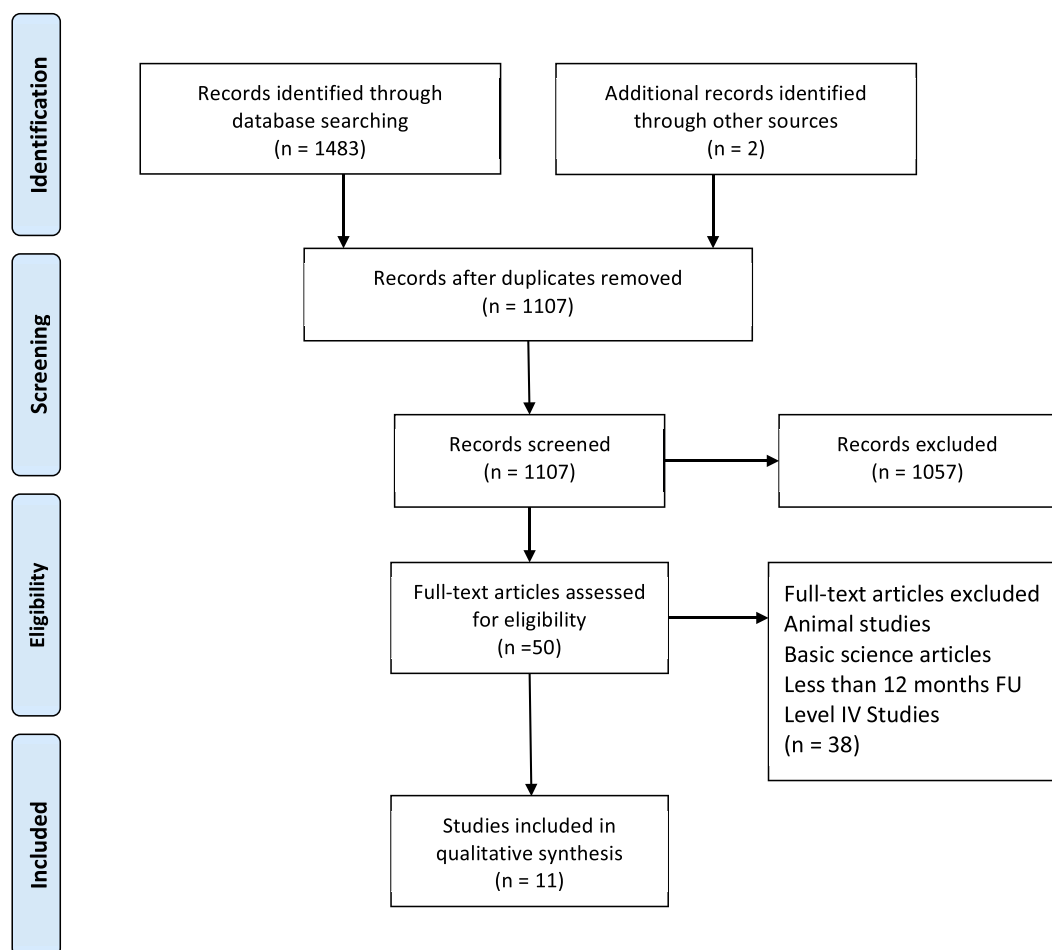


Fig. 1. Flow diagram presenting the systematic review process used in this study.

revascularization can occur with restoration of bone formation and remodeling. However, long-term results on this procedure can be unpredictable [7], and its efficacy remains an area of controversy [6].

Currently, there is no consensus regarding the treatment of early stages of ONFH [2]. Although a variety of treatments, ranging from nonoperative (eg, bisphosphonates) to operative (CD, bone grafting, vascularized fibular grafting, rotational osteotomy, etc.) have been proposed, none of these have been proven to be clearly superior so that widespread adoption has occurred. To date, THA is the most frequent intervention for postcollapse treatment, and CD is commonly performed for symptomatic, precollapse cases [8]. Adjunctive techniques have been described in an attempt to improve CD outcomes, and specifically cell-based therapies are being explored to restore the local cell population and to establish effective bone remodeling [9,10]. The purpose of the present study was to provide a systematic review of the current literature on the use of cell-based therapies for the treatment of ONFH. Our specific aims were to examine the evidence supporting their (1) clinical efficacy; (2) structural modifying effect, as evaluated radiographically; (3) revision rates; and (4) safety.

Materials and Methods

Article Identification and Selection

This study was conducted in accordance with the 2009 Preferred Reporting Items for Systematic Review and Meta-Analysis statement

[11]. Reports were identified by using an electronic search of keyword terms and combinations. A systematic review of the literature regarding the cell therapy treatment of ONFH in human patients was performed using the Cochrane Database of Systematic Reviews, the Cochrane Central Register of Controlled Trials, PubMed (1990–2016), and Medline (1990–2016). The queries were performed in October of 2016.

Four different searching criteria were used, using the search terms: cell-therapy, stem-cells, hip, osteonecrosis, and avascular necrosis:

Search 1

("cell- and tissue-based therapy"[MeSH Terms] OR ("cell"[All Fields] AND "tissue-based"[All Fields] AND "therapy"[All Fields]) OR "cell- and tissue-based therapy"[All Fields] OR ("cell"[All Fields] AND "therapy"[All Fields]) OR "cell therapy"[All Fields]) AND ("hip"[MeSH Terms] OR "hip"[All Fields])

Search 2

("stem cells"[MeSH Terms] OR ("stem"[All Fields] AND "cell-s"[All Fields]) OR "stem cells"[All Fields] OR ("stem"[All Fields] AND "cell"[All Fields]) OR "stem cell"[All Fields]) AND ("hip"[MeSH Terms] OR "hip"[All Fields])

Search 3

("osteonecrosis"[MeSH Terms] OR "osteonecrosis"[All Fields] OR ("avascular"[All Fields] AND "necrosis"[All Fields]) OR "avascular

Table 1
Demographic Data of the Included Studies.

Author	Country	Year	Journal	Ev Study Design	Type	Treatment	Male	Female	Number Cases (Hips)	Mean Age	Mean F/U, mo	Etiogenic	Ficat Classification	ARCO Classification	Japanese Orthopaedic Association Staging	Mitchell Staging
Rastogi et al [15]	India	2013	Musculoskeletal Surgery	III RCT	Control	CD + unprocessed bone marrow	3/1 Ratio		30	33	24	Idiopathic (46%); Alcohol (7%); Smoking (13%); Steroid (33%)	N/A	IB (2), IC (5), IIB (3), IIC (8), IIB (5), and IIC (7).	N/A	N/A
					Study	CD + cells	5/2 Ratio		30	34.67	Idiopathic (40%); Alcohol (20%); Smoking (13%); Steroid (27%)	N/A	IB (2), IC (5), IIB (3), IIC (8), IIB (5), and IIC (7).	N/A	N/A	
Sen et al [16]	India	2012	The Journal of Arthroplasty	II RCT	Control	CD	18	7	25	N/A	24	Traumatic 17 hips; nontraumatic 34 hips, 8 long-term alcoholism, 2 idiopathic, 2 pregnancy-induced, and 2 Cushing disease	N/A	N/A	N/A	A (7), B (4), C (8), and D (1)
					Study	CD + cells	19	7	26		26	8 long-term alcoholism, 2 idiopathic, 2 pregnancy-induced, and 2 Cushing disease	N/A	N/A	N/A	A (6), B (9), C (11), and D (0)
Mao et al [17]	China	2015	Journal of Bone and Mineral Research	I RCT	Control	Porous tantalum rod	13	12	41	36.12	36	Idiopathic (29%); Alcohol (34%); Steroid (36%)	N/A	I (10), II (23), IIIA (8)	N/A	N/A
					Study	Porous tantalum rod + intraarterial cell infusion	17	13	48	34.6	36	Idiopathic (29%); Alcohol (37%); Steroid (33%)	N/A	I (8), II (29), IIIA (11)	N/A	N/A
Ma et al [18]	China	2014	Stem Cell Research & Therapy	I RCT	Control	CD + autologous bone graft	13	5	24	34.78	24	Idiopathic (6); Alcohol (3); Steroid (13)	I (4), II (15), III (5)	N/A	N/A	N/A
					Study	CD + autologous bone graft + cells	15	6	25	35.6	24	Idiopathic (6); Alcohol (4); Steroid (13)	I (3), II (17), III (5)	N/A	N/A	N/A
Zhao et al [19]	China	2012	Bone	I RCT	Control	CD	26	24	51	33.8	60	Trauma (12); Idiopathic (13); Alcohol (7); Steroid (13); Caisson disease (5)	N/A	IC (2), IIA (15), IIB (22), IIC (12)	N/A	N/A
					Study	CD + cells	27	23	53	32.7	60	Trauma (8); Idiopathic (16); Alcohol (11); Steroid (10); Caisson disease (5)	N/A	IC (4), IIA (15), IIB (23), IIC (11)	N/A	N/A
Tabatabaee et al [20]	Iran	2015	The Journal of Arthroplasty	I RCT	Control	CD	10	4	14	26.8	24	Idiopathic (36%); Steroid (64%)	N/A	I (2), II (7), III (5)	N/A	N/A
					Study	CD + cells	9	5	14	31	24	Idiopathic (29%); Steroid (71%)	N/A	I (3), II (9), III (2)	N/A	N/A
Gangji et al [21]	Belgium	2011	Bone	I RCT	Control	CD	9	10	11	45.7	60	Idiopathic (1); Alcohol (1); Steroid (9)	N/A	I (2), II (9)	N/A	N/A
					Study	CD + cells			13	42.2	60	Idiopathic (1); Alcohol (1); Steroid (11)	N/A	I (2), II (11)	N/A	N/A

(continued on next page)

Table 1 (continued)

Author	Country	Year	Journal	Ev	Study Design	Type	Treatment	Male	Female	Number Cases (Hips)	Mean Age	Mean F/U, mo	Etiogenic	Ficat Classification	ARCO Classification	Japanese Orthopaedic Association Staging	Mitchell Staging
Lim et al [22]	Korea	2013	Experimental & Molecular Medicine	III	Retrospective Cohort Study	Control	CD + curettage + bone graft	16	5	31	34.4	60	Idiopathic (10); Steroid (6); Alcohol (4); other (1)	I (0), IIa (14), IIb (9), III (8)	N/A	N/A	N/A
						Study	Multiple drilling + cells	69	17	128	36.3	60	Idiopathic (15); Steroid (48); Alcohol (20); other (3)	I (0), IIa (42), IIb (37), III (49)	N/A	N/A	N/A
Liu et al [23]	China	2013	Archives of Orthopaedic and Trauma Surgery	III	Retrospective Cohort Study	Control	CD + hydroxyapatite bone filler	14	3	27	38.1	24.9	Idiopathic (4); Steroid (9); Alcohol (14)	N/A	IIB (12), IIC (15)	N/A	N/A
						Study	CD + hydroxyapatite bone filler + cells	13	4	28	38	26.7	Idiopathic (3); Steroid (10); Alcohol (15)	N/A	IIB (13), IIC (15)	N/A	N/A
Yamasaki et al [24]	Japan	2010	The Journal of Bone and Joint Surgery (British volume)	III	Retrospective Cohort Study	Control	CD + calcium hydroxyapatite bone filler	7	1	9	49	31	Idiopathic (3); Steroid (2); Alcohol (4)	N/A	N/A	II (8)	N/A
						Study	CD + calcium hydroxyapatite bone filler + cells	14	8	30	41	29	Idiopathic (2); Steroid (22); Alcohol (6)	N/A	N/A	I (2), II (25), IIIA (3)	N/A
Pepke et al [25]	Germany	2016	Orthopedic Reviews	I	RCT	Control	CD	12	2	14	45	24	Idiopathic (9); Chemotherapy (2); Immunosuppression (3)	N/A	II (14)	N/A	N/A
						Study	CD + cells	10	1	11	44.3	24	Idiopathic (10); Chemotherapy (0); Immunosuppression (1)	N/A	II (11)	N/A	N/A

CD, core decompression; Ev, level of evidence; F/U, follow-up; N/A, not available; RCT, randomized controlled trial; ARCO, Association Research Circulation Osseous.

Table 2
Outcome Analysis of the 11 Studies Included.

Author	Group	Treatment	Number of ONFH	Clinical Outcome	Radiological Outcome	Revision Rate—THA
Rastogi et al 2013 [15]	Control	CD + unprocessed bone marrow	30			
	Study	CD + cells	30	↑	↑★	↑★
Sen et al 2012 [16]	Control	CD	25		=	N/A
	Study	CD + cells	26	↑★	=	N/A
Mao et al 2015 [17]	Control	Porous tantalum rod	41			
	Study	Porous tantalum rod + intraarterial cell infusion	48	↑★	↑★	↑★
Ma et al 2014 [18]	Control	CD + autologous bone graft	24			
	Study	CD + autologous bone graft + cells	25	↑★	↑★	↑★
Zhao et al 2012 [19]	Control	CD	51			
	Study	CD + cells	53	↑★	↑★	↑★
Tabatabaee et al 2015 [20]	Control	CD	14			
	Study	CD + cells	14	↑★	↑★	↑★
Gangji et al 2011 [21]	Control	CD	11			
	Study	CD + cells	13	↑★	↑★	↑★
Lim et al 2013 [22]	Control	CD + curettage + bone graft	31	=	=	=
	Study	CD + cells	128	=	=	=
Liu et al 2013 [23]	Control	CD + hydroxyapatite bone filler	27			
	Study	CD + hydroxyapatite bone filler + cells	28	↑★	↑★	↑★
Yamasaki et al 2010 [24]	Control	CD + calcium hydroxyapatite bone filler	9			
	Study	CD + calcium hydroxyapatite bone filler + cells	30	↑	↑★	↑★
Pepke et al 2016 [25]	Control	CD	14			
	Study	CD + cells	11	↑	↑	↑

=, no difference; ↑, better result; ★, significant difference ($P < .05$); CD, core decompression; N/A, not available; ONFH, osteonecrosis of the femoral head; THA, total hip arthroplasty.

necrosis"[All Fields]) AND ("hip"[MeSH Terms] OR "hip"[All Fields]) AND ("cell- and tissue-based therapy"[MeSH Terms] OR ("cell"[All Fields] AND "tissue-based"[All Fields] AND "therapy"[All Fields]) OR "cell- and tissue-based therapy"[All Fields] OR ("cell"[All Fields] AND "therapy"[All Fields]) OR "cell therapy"[All Fields])

Search 4

(("osteonecrosis"[MeSH Terms] OR "osteonecrosis"[All Fields] OR "avascular"[All Fields] AND "necrosis"[All Fields]) OR "avascular necrosis"[All Fields] AND ("hip"[MeSH Terms] OR "hip"[All Fields])) AND ("stem cells"[MeSH Terms] OR ("stem"[All Fields] AND "cells"[All Fields]) OR "stem cells"[All Fields])

Studies were included in this systematic review if the reports contained clinical and/or radiological outcomes for cell therapy in the treatment of ONFH with a minimum follow-up of 12 months, and had a level of evidence of I, II, or III. All included articles were presented in the English language, and were performed on human subjects. Exclusion criteria were as follows: cadaveric studies, animal studies, basic science articles, editorials, surveys, special topics, letters to the editor, and personal correspondence.

Two authors performed the initial search (N. S. P., J. C.), and three investigators (N. S. P., C. P. G., J. C.) independently reviewed the abstracts from all identified articles and inclusion and exclusion criteria were applied based on the information presented therein. If one or more authors selected an article, it progressed to the following phase. Full-text articles were obtained to allow further assessment of inclusion and exclusion criteria, as needed. In addition, all references from the included studies were reviewed and reconciled to verify that no relevant articles were missing from the systematic review.

Level-of-evidence was assigned using classifications specified by Wright et al [12]. Data were recorded into a custom information extraction table [13].

Study Selection

Our initial systematic literature review yielded 1483 individual studies, of which 12 met the inclusion criteria and were

identified and included for analysis (Fig. 1). One study was excluded after communication with the authors to avoid patient duplication [14]. After review of the 11 remaining reports according to the level of evidence, 6 were level I, 1 was level II, and 4 were level III.

Patient Demographics

The 11 studies included 528 ONFH patients, as summarized in Table 1. Of the 683 hips, 416 hips received a cell therapy procedure for the treatment of ONFH and 155 were bilateral. Mean patient age was 37 years (range 27–49 years). The classification systems used were: Association Research Circulation Osseous classification [26,27]: 47 (grade I); 288 (grade II); and 50 (grade III) [14,15,17,19–21]. Ficat classification [28]: 7 (grade I); 134 (grade II); and 67 (grade III) [18,22]. Japanese Orthopaedic Association Staging: 2 (grade I), 25 (grade II), 3 grade IIIA and Mitchell staging system: 13 (grade A); 13 (grade B); 19 (grade C); and 1 (grade D) (5 patients were not classified according to the MRI Mitchell's classification because of hardware presence) [16]. From this data, it can be calculated that 81% of the studied hips were Ficat stages 1–2. Mean follow-up was 37 months (range 24–60 months).

Clinical Efficacy—Patient-Reported Outcome Measures

Ten of the 11 studies [15–25] analyzed the outcome of treatment in the cell therapy and control treatment groups using patient-reported outcomes (PROs; Tables 2 and 3). Three studies reported pretreatment and follow-up status using Western Ontario and McMaster Universities Arthritis Index (WOMAC) score [18,20,21]; and 6 studies reported pain using a visual analog scale (VAS) [14,18,20,21,23,25]. Six studies reported Harris Hip Score (HHS) outcomes [15–17,23,25]; however, one study did not include standard deviations [15]. Two studies [18,21] reported baseline and follow-up status using a Lequesne index. One study reported clinical outcome with the System of Merle d'Aubigne and Postel [24].

Table 3
Clinical Outcome.

Author	Group	Treatment	Number of ONFH	VAS Baseline, mm	VAS F/U (mm)	WOMAC Baseline	WOMAC F/U	Lequesne Index Baseline	Lequesne Index F/U	HHS Baseline	HHS F/U	System of Merle d'Aubigne and Postel Baseline	System of Merle d'Aubigne and Postel F/U
Rastogi et al 2013 [15]	Control	CD + unprocessed bone marrow	30	N/A	N/A	N/A	N/A	N/A	N/A	47.08	66.8	N/A	N/A
Sen et al 2012 [16]	Study	CD + cells	30	N/A	N/A	N/A	N/A	N/A	N/A	46.75	78.6	N/A	N/A
	Control	CD	25	N/A	N/A	N/A	N/A	N/A	N/A	65.7 ± 15.2	77.4 ± 17.0	N/A	N/A
Mao et al 2015 [17]	Study	CD + cells	26	N/A	N/A	N/A	N/A	N/A	N/A	66.2 ± 13.0	82.4 ± 9.6	N/A	N/A
	Control	Porous tantalum rod	41	N/A	N/A	N/A	N/A	N/A	N/A	64.6 ± 8.6	78.5 ± 8.7	N/A	N/A
Ma et al 2014 [18]	Study	Porous tantalum rod + intraarterial cell infusion	48	N/A	N/A	N/A	N/A	N/A	N/A	62.7 ± 11.1	88.1 ± 3.3	N/A	N/A
	Control	CD + autologous bone graft	24	35.2 ± 3.4	26.5 ± 2.6	24 ^a	22 ^a	9.8	7 ^a	N/A	N/A	N/A	N/A
Zhao et al 2012 [19]	Study	CD + autologous bone graft + cells	25	35.6 ± 4.2	16.9 ± 3.7	27.8 ± 4.2	14.8 ± 3.0	9.6 ± 1	5.8 ± 1	N/A	N/A	N/A	N/A
	Control	CD	51	N/A	N/A	N/A	N/A	N/A	N/A	CD + cells compared to CD alone contributed to greater improvement of HHS in hips of Stages IC ($P < .01$), IIA ($P = .06$), IIB ($P < .01$), and IIC ($P = .02$). Mean HHS of CDC + cells treated hips of each stage, was statistically higher than that of CDC alone.		N/A	N/A
Tabatabaee et al 2015 [20]	Study	CD + cells	53	N/A	N/A	N/A	N/A	N/A	N/A	N/A	N/A	N/A	N/A
	Control	CD	14	38.6 ± 4.6	32.0 ± 4.4	35.9 ± 2.7	27.2 ± 3.7	N/A	N/A	N/A	N/A	N/A	N/A
Gangji et al 2011 [21]	Study	CD + cells	14	35.9 ± 4.5	16.0 ± 2.5	32.0 ± 3.8	9.7 ± 1.8	N/A	N/A	N/A	N/A	N/A	N/A
	Control	CD	11	46.0 ± 7.2	51 ^a	30.5 ± 5.5	CD + cells did not improve WOMAC score compared with the control group ($P = .091$)	8.6 ± 1.4	9 ^a	N/A	N/A	N/A	N/A
Lim et al 2013 [22]	Study	CD + cells	13	32.8 ± 7.1	20.8 ± 7.7	25.5 ± 4.5		7.2 ± 1.2	4.8 ± 1.8	N/A	N/A	N/A	N/A
	Control	CD	31	N/A	N/A	N/A	N/A	N/A	N/A	N/A	N/A	N/A	N/A
Liu et al 2013 [23]	Study	Multiple drilling + cells	128	N/A	N/A	N/A	N/A	N/A	N/A	N/A	N/A	N/A	N/A
	Control	CD + hydroxyapatite bone filler	27	64.6 ± 2.9	30 ^a	N/A	N/A	N/A	N/A	64 ^a	76 ^a	N/A	N/A
Yamasaki et al 2010 [24]	Study	CD + hydroxyapatite bone filler + cells	28	63.6 ± 2.6	20 ^a	N/A	N/A	N/A	N/A	64 ^a	80 ^a	N/A	N/A
	Control	CD + calcium hydroxyapatite bone filler	9	N/A	N/A	N/A	N/A	N/A	N/A	N/A	N/A	15.2 (14-17)	14.2 (12-15)
Pepke et al 2016 [25]	Study	CD + calcium hydroxyapatite bone filler + cells	30	N/A	N/A	N/A	N/A	N/A	N/A	N/A	N/A	14.7 (13-16)	17 (15-18)
	Control	CD	14	57 ^a	26 ^a	N/A	N/A	N/A	N/A	61 ^a	75 ^a	N/A	N/A
	Study	CD + cells	11	48 ^a	23 ^a	N/A	N/A	N/A	N/A	61 ^a	81 ^a	N/A	N/A

CD, core decompression; F/U, follow-up; HHS, Harris Hip Score; N/A, not available; ONFH, osteonecrosis of the femoral head; THA, total hip arthroplasty; VAS, visual analogue scale; WOMAC, Western Ontario & McMaster Universities Arthritis Index score.

^a Data estimated from figures.

Table 4
Structural Assessment—Imaging.

Author	Treatment	Number Cases (ONFH)	Baseline Assessment	Follow-Up Assessment	Time, mo	Lesion Size Baseline	Lesion Size Follow-Up
Rastogi et al 2013 [15]	CD + unprocessed bone marrow	30	ARCO: IB (2), IC (5), IIB (3), IIC (8), IIIB (5), and IIIC (7).	MRI—Kerboul angle analysis: Mean increase of 1.08°	24	N/A	N/A
	CD + cells	30	ARCO: IB (2), IC (5), IIB (3), IIC (8), IIIB (5), and IIIC (7).	MRI—Mean decrease of 6.1° ($P = .03$)		N/A	N/A
Sen et al 2012 [16]	CD	25	A—fat (7), B—blood (4), C—fluid (8), and D—fibrosis (1)	No significant difference in overall improvement of MRI features between the 2 groups	24	Moderate (4), extensive (16)	N/A
	CD + cells	26	A (6), B (9), C (11), and D (0)			Moderate (14), extensive (12)	N/A
Mao et al 2015 [17]	Porous tantalum rod	41	ARCO: I (10), II (23), IIIA (8)	Radiological progression: 13; Radiological collapse: 5 ARCO I (9), II (21), III (8), IV (3)	36	N/A	N/A
	Porous tantalum rod + intraarterial cell infusion	48	ARCO: I (8), II (29), IIIA (11)	Radiological progression: 4; Radiological collapse: 3 ARCO I (9), II (24), III (11), IV (4)	36	N/A	N/A
Ma et al 2014 [18]	CD + autologous bone graft	24	Ficat: I (4), II (15), III (5)	Radiological progress rate: 33.3%; Progress rate for early-stage (I/II) hips: 33.3%	24	N/A	N/A
	CD + autologous bone graft + cells	25	Ficat: I (3), II (17), III (5)	Radiological progress rate: 8%; Progress rate for early-stage (I/II): 0%	24	N/A	N/A
Zhao et al 2012 [19]	CD	51	ARCO: IC (2), IIA (15), IIB (22), IIC (12)	MRI—20% (10 of 51) hips progressed to stage III or IV	60	N/A	N/A
	CD + cells	53	ARCO: IC (3), IIA (15), IIB (23), IIC (10)	MRI—4% (2 of 53) hips progressed to stage III	60	N/A	N/A
Tabatabaee et al 2015 [20]	CD	14	ARCO: I (2), II (7), III (5), Mean MRI score 2.2, mean MRI rank 16	Mean MRI score 2.8, mean MRI rank 18.6, progress rate 10/14 hips (71%)	24	N/A	N/A
	CD + Cells	14	ARCO: I (3), II (9), III (2), mean MRI score 1.93, mean MRI rank 12.9	Mean MRI score 1.7, mean MRI rank 8.5, progress rate 0%, 1 hip improved from III to II, 1 improved from II to I	24	N/A	N/A
Gangji et al 2011 [21]	CD	11	ARCO: I (2) II (9)	MRI—73% (8 of 11) hips had deteriorated to stage III	60	volume of lesion/volume of femoral head (%) 19.2 ± 3.9	Lesion size decreased 22% at 60 mo follow-up.
	CD + cells	13	ARCO: I (2) II (11)	MRI—23% (3 of 13) hips had deteriorated to stage III	60	Volume of lesion/volume of femoral head (%) 16.0 ± 2.2	Lesion size decreased 42% at 60 mo follow-up.
Lim et al 2013 [22]	CD + curettage + bone graft	31	Ficat: I (0), IIA (14), IIB (9), III (8)	45% (14 of 31) considered unsuccessful	60	N/A	N/A
	Multiple drilling + cells	128	Ficat: I (0), IIA (42), IIB (37), III (49)	46% (59 of 128) hips considered unsuccessful	60	N/A	N/A
Liu et al 2013 [23]	CD + hydroxyapatite bone filler	27	ARCO: IIB (12), IIC (15)	40.7% considered radiological success, 16/27 (59.3%) of hips exhibited collapse or aggravated collapse	25	N/A	N/A
	CD + hydroxyapatite bone filler + cells	28	ARCO: IIB (13), IIC (15)	78.6% considered radiological success, 6/28 (21.4%) of hips exhibited collapse or aggravated collapse	27	N/A	N/A

(continued on next page)

Table 4 (continued)

Author	Treatment	Number Cases (ONFH)	Baseline Assessment	Follow-Up Assessment	Time, mo	Lesion Size Baseline	Lesion Size Follow-Up
Yamasaki et al 2010 [24]	CD + calcium hydroxyapatite bone filler	9	JOA II (8)	MRI—mild collapse 3 hips (33%), severe collapse >2 mm in 6 hips (77%)	18	Method Steinberg, 22% (14%–55%)	N/A
	CD + calcium hydroxyapatite bone filler + cells	30	JOA I (2), II (25), IIIA (3)	MRI—No progression 17 hips (57%), mild collapse 10 hips (33%), Severe collapse >2 mm in 3 hips (10%)	18	Method Steinberg, 21% (3%–36%)	Method Steinberg, 8% (0.6%–16%)
Pepke et al 2016 [25]	CD	14	ARCO: II (14)	MRI—head survival rate of 8/14 (57%)	24	N/A	N/A
	CD + cells	11	ARCO: II (11)	MRI—head survival group 7/11 (64%)	24	N/A	N/A

CD, core decompression; MRI, magnetic resonance imaging; N/A, not available; ONFH, osteonecrosis of the femoral head; ARCO, Association Research Circulation Osseous; JOA, Japanese Orthopaedic Association.

Structural Modifying Effect—Structural Assessment With Images

All 11 studies performed imaging structural assessments. Seven studies [15,16,19–21,24,25] did structural assessments with magnetic resonance imaging (MRI) (Tables 2 and 4), and 4 studies assessed disease progression through x-ray evaluation only [17,18,22,23,29]. Two hundred sixty-eight hips in 6 studies [15,16,18,20,23,25] were followed up for 24 months; 286 hips in 3 studies [19,21,22] were followed up for 60 months, 89 hips in one study [17] were followed up for 36 months, and 39 hips in one study were followed up for 18 months [24].

Revision Rates—Conversion to THA

Ten of the 11 studies reported failure rates based on conversion to THA [15,17–25].

Safety—Complications

Complications were reported in all 11 studies, although one of them did not provide details, and was excluded for the analysis [22].

Results

Overall cell therapies showed improved clinical outcome, decreased radiographic progression and decreased revision rate (Table 2).

Clinical Efficacy—Patient-Reported Outcome Measures

All 10 studies that reported PROs showed improved outcomes in the cell therapy groups (278 hips) compared with control groups (254 hips) (Table 3). The 5 studies that reported pain according to VAS demonstrated substantial improvement in cell therapy groups (91 hips) compared with control groups (90 hips) [2,16,19,24,30]. Two of these 5 studies reported similar favorable findings with WOMAC score evaluations (39 hips treated with cell therapy vs 38 hips treated with control group) [16,24], although one study [21] did not find differences between the cell therapy (13 hips) and the control group (11 hips). Nonetheless, this later study included the Lequesne index and reported significant difference in favor of cell therapy group (13 hips), compared with control group (11 hips) [21].

All 6 studies that provided a HHS score assessment showed improvement in both cell therapies (188 hips) and control groups (196 hips). Nevertheless, the improvement was greater among the cell therapy groups among the 6 studies [15–17,19,23,25].

Structural Modifying Effect—Structural Assessment With Images

Nine studies demonstrated a reduced progression, no progression, or even regression of ONFH lesions with the use of cell therapies (221 hips) compared with control groups (252 hips) [15–21,24,25]. In contrast, 2 studies [16,22] found no significant differences by MRI with the use of cell therapy (154 cell therapy cases vs 56 controls). Overall, 24.5% (93/380 hips) that received cell therapy showed radiographic progression compared with 40% (98/245 hips) in the control group (Table 4).

Revision Rate—Conversion to THA

Nine of 10 studies that reported revision rates showed a lower THA conversion rate in the cell therapy group 16% (62/380 hips) compared with the control group 21% (52/252 hips); however, the

Table 5
Complications and Failure Rate.

Author	Type	Treatment	Number Cases (ONFH)	Complications	Revision Rate—Conversion to THA
Rastogi et al 2013 [15]	Control	CD + unprocessed bone marrow	30	0	3 (10%)
	Study	CD + cells	30	0	0
Sen et al 2012 [16]	Control	CD	25	0	N/A
	Study	CD + cells	26	0	N/A
Mao et al 2015 [17]	Control	Porous tantalum rod	41	1 (infection)	9 (21.95%)
	Study	Porous tantalum rod + intraarterial cell infusion	48	1 displacement of the rod	3 (6.25%)
Ma et al 2014 [18]	Control	CD + autologous bone graft	24	0	4 (16.6%)
	Study	CD + autologous bone graft + cells	25	0	2 (8%)
Zhao et al 2012 [19]	Control	CD	51	0	5 (5%)
	Study	CD + cells	53	0	0
Tabatabaee et al 2015 [20]	Control	CD	14	0	3 (21%)
	Study	CD + cells	14	0	0
Gangji et al 2011 [21]	Control	CD	11	1 hematoma at side of the CD	3 (27.3%)
	Study	CD + cells	13	3 pain at the donor side/1 "infection"	2 (15.4%)
Lim et al 2013 [22]	Control	CD + curettage + bone graft	31	N/A	11 (35.5%)
	Study	Multiple drilling + cells	128	N/A	47 (36.7%)
Liu et al 2013 [23]	Control	CD + hydroxyapatite bone filler	27	Guidewire breakages (2), perforation of the subchondral bone (3)	5 (19%)
	Study	CD + hydroxyapatite bone filler + cells	28	Guidewire breakages (2), perforation of the subchondral bone (1)	4 (14%)
Yamasaki et al 2010 [24]	Control	CD + calcium hydroxyapatite bone filler	9	0	3 (33%)
	Study	CD + calcium hydroxyapatite bone filler + cells	30	0	1 (3%)
Pepke et al 2016 [25]	Control	CD	14	0	6 (43%)
	Study	CD + cells	11	0	4 (36%)

CD, core decompression; N/A, not available; ONFH, osteonecrosis of the femoral head; THA, total hip arthroplasty.

difference was not significant in all studies: 0/10 to 3/30 (10%) [15]; 3/48 (6%) to 9/41 (22%) ($P = .031$) [17]; 2/25 (9%) to 4/24 (22%) [18]; 0/53 to 5/51 (11%) ($P < .05$) [19]; 2/13 (15%) to 3/11 (27%) ($P = .008$) [21]; 4/28 (14%) to 5/27 (19%) [23]; 1/30 (3%) to 3/9 (33%) [24]; 0/14 to 3/14 (21%) [20] and 4/11 (36%) to 6/14 (43%) ($P > .05$) [25] (see Table 5). Only one study had a higher THA conversion rate in the cell therapy group: 47/128 (37%) to 11/31 (35%) ($P < .8527$) [22], although this difference was not statistically significant.

Safety—Complications

From the 10 included studies (524 hips) that provided data on complications, there were a total of 15/524 (2.8%) reported complications (Table 5). For these minor complications, 6 complications appeared in the control group (6 adverse events/246 hips: 2.4%), and 8 complications in the cell therapy group (8 adverse/278 hips: 2.9%). There were no major adverse effects reported. The most common complaint was pain in association with a hematoma at the site of the CD and pain at the bone marrow aspiration site. Two patients had an infection [18,21]. One of the patients presented with a positive bacteriological culture of the bone marrow (coagulase negative staphylococci) and was treated with antibiotics, but had no clinical symptoms of sepsis [21]. The other patient was in a control group and experienced a postoperative infection that was successfully treated with antibiotics [17]. We did not find significant difference between cell therapy groups and control groups in terms of complications, and there were no reported events related to the cell therapy, no constitutional symptoms reported.

Discussion

The most important findings of this study were that the utilization of cell therapies in patients with early stages of ONFH when compared with their control groups showed overall: (1) favorable

results based on PROs; (2) a lower disease progression rate; (3) a lower failure rate; and (4) safety in the use of cell-based therapies with rare and minor complications.

Our systematic review had several limitations. First, there was a wide variation in the cell-based therapies used, specifically regarding the choice of cells, method of cell processing, cell characterization, quantitative and qualitative assessment of the cells used, surgical methods of cell delivery, the attributes of patient cohorts, and the outcome measures used. As a result, generalizable conclusions regarding the magnitude of treatment effect and the relative efficacy between the treatment strategies that have been evaluated must be made with caution. Second, the selection for success or failure was determined mainly by the end point of patient undergoing a THA, which may not be the most accurate measure. Third, although 81% of the studied hips were classified as Ficat stage I and stage II, we could not consistently analyze and correlate the size of lesion with progression, because it was infrequently reported. Fourth, the results presented in this study have a mean follow-up of 37 months (range 24–60 months), which could underestimate the progression and failure rate of these therapies. Despite these variations and limitations noted, these studies demonstrated generally beneficial effects of the cell-based therapies that warrant further investigation.

In each study, improvements in one or more PRO were reported for cell therapy groups when compared with non-cell therapy groups was found [15–25]. In our assessment, cell therapy with CD treatment showed improvement in modified Harris Hip Score, VAS, and WOMAC scores when compared with CD alone. Our findings are supported by other preclinical and clinical reviews on the use of cell therapy for the treatment of ONFH [29,31]. After pain and function, conversion to THA can be considered to be the next most important outcome. Eight of 9 studies [15,17–19,21,23–25] reporting on THA conversion reported lower rates in the cell therapy treatment groups. These reports should be considered positively and

may be promising. However, it must also be recognized that the decision to offer THA and the decision to accept THA are subjective decisions that are not immune from bias without double blind study design. Conversely structural modifying effect measured both by MRI and x-ray showed that cell-based therapies decreased the progression rate, with a more significant effect among earlier stages of ONFH.

The only study that did not encounter positive results in any aspect analyzed was Lim et al [22]. However, looking at the data, it appears that the cell group had a number of factors that could have introduced bias and predisposed to worse results: (1) steroid was the cause of ONFH in 56% of cases in the cell therapy group, whereas in the control group, it was 29% and (2) underlying disease in the cell therapy group comprised between leukemia, aplastic anemia, and kidney transplantation a 47%, whereas in the control group, it was 19%. These differences might have introduced bias because these causes are known to have worst result not only in hip preservation procedures but also in THA [1,2,4,6,30].

Based on the current literature, the use of cell therapies has been reported to be safe in multiple orthopedic settings [32–36]. In this study, the rate of complications was low, and we did not find any difference between the cell therapy group and control group. All complications reported were related to donor site morbidity, from the harvest site and there were no reports of complications attributed to the delivery of cells or follow-up.

At early stages of ONFH, hip preservation techniques are often preferred, specifically in younger patients [2,8,37–39]. The rationale for the use of a cell therapy approach is that regions of osteonecrosis can only be repaired by bone regeneration and remodeling through the action of bone forming osteogenic progenitors. As regenerative medicine and the application of cell therapies become available, a better understanding of these treatments will be required. Among the pool of “cell-based therapies”, more diversity was present, and stem and progenitor cell population varied among (1) sources; (2) patients; and (3) processing methods. Cell types available to be used may include (1) autologous or allogenic cells; (2) adult, embryonic, or induced pluripotential stem cells; and (3) native (tissue resident) stem and progenitor cells or cultured expanded cells (eg, mesenchymal stromal cells) [40–52]. The analysis and description of these heterogeneous cell therapy options are beyond the scope of this article.

Conclusion

Cell therapies in patients with early stages of ONFH suggest (1) improved clinical outcomes; (2) decreased radiographic progression of disease; (3) decreased revision rate; and (4) a low complication rate. There was a high heterogeneity in cell therapies used and the outcome measures selected. Cell therapies offer a promising future; nevertheless, its propagation and acceptance will demand the implementation of standardization to allow reproducibility. Additional blinded randomized control trials and clinical effectiveness trials with rigorous standards are needed to establish the efficacy of these therapies for the treatment of ONFH.

References

- Mont MA, Hungerford DS. Non-traumatic avascular necrosis of the femoral head. *J Bone Joint Surg Am* 1995;77:459.
- Moya-Angeler J, Ariana G, Jordan CV, et al. Current concepts on osteonecrosis of the femoral head. *World J Orthop* 2015;6:590.
- Shah KN, Racine J, Jones LC, et al. Pathophysiology and risk factors for osteonecrosis. *Curr Rev Musculoskelet Med* 2015;8:201.
- Mont MA, Zywiell MG, Marker DR, et al. The natural history of untreated asymptomatic osteonecrosis of the femoral head: a systematic literature review. *J Bone Joint Surg Am* 2010;92:2165.
- Daltro GC, Fortuna V, de Souza ES, et al. Efficacy of autologous stem cell-based therapy for osteonecrosis of the femoral head in sickle cell disease: a five-year follow-up study. *Stem Cell Res Ther* 2015;6:110.
- Pierce TP, Jauregui JJ, Elmallah RK, et al. A current review of core decompression in the treatment of osteonecrosis of the femoral head. *Curr Rev Musculoskelet Med* 2015;8:228.
- Koo KH, Kim R, Ko GH, et al. Preventing collapse in early osteonecrosis of the femoral head. A randomised clinical trial of core decompression. *J Bone Joint Surg Br* 1995;77:870.
- McGrory BJ, York SC, Iorio R, et al. Current practices of AAHKS members in the treatment of adult osteonecrosis of the femoral head. *J Bone Joint Surg Am* 2007;89:1194.
- Bianco P, Riminucci M, Gronthos S, et al. Bone marrow stromal stem cells: nature, biology, and potential applications. *Stem Cells* 2001;19:180.
- Hernigou P, Flouzat-Lachaniette CH, Delambre J, et al. Osteonecrosis repair with bone marrow cell therapies: state of the clinical art. *Bone* 2014;70:102.
- Moher D, Liberati A, Tetzlaff J, et al. Preferred reporting items for systematic reviews and meta-analyses: the PRISMA statement. *Ann Intern Med* 2009;151:264.
- Wright JG, Swiontkowski MF, Heckman JD. Introducing levels of evidence to the journal. *J Bone Joint Surg Am* 2003;85-A:1.
- Harris JD, Quatman CE, Manring MM, et al. How to write a systematic review. *Am J Sports Med* 2014;42:2761.
- Gangji V, Hauzeur J-P, Matos C, et al. Treatment of osteonecrosis of the femoral head with implantation of autologous bone-marrow cells. A pilot study. *J Bone Joint Surg Am* 2004;86:1153.
- Rastogi S, Sankineani SR, Nag HL, et al. Intralesional autologous mesenchymal stem cells in management of osteonecrosis of femur: a preliminary study. *Musculoskelet Surg* 2013;97:223.
- Sen RK, Tripathy SK, Aggarwal S, et al. Early results of core decompression and autologous bone marrow mononuclear cells instillation in femoral head osteonecrosis. A randomized control study. *J Arthroplasty* 2012;27:679.
- Mao Q, Wang W, Xu T, et al. Combination treatment of biomechanical support and targeted intra-arterial infusion of peripheral blood stem cells mobilized by granulocyte-colony stimulating factor for the osteonecrosis of the femoral head: a randomized controlled clinical trial. *J Bone Miner Res* 2015;30:647.
- Ma Y, Wang T, Liao J, et al. Efficacy of autologous bone marrow buffy coat grafting combined with core decompression in patients with avascular necrosis of femoral head: a prospective, double-blinded, randomized, controlled study. *Stem Cell Res Ther* 2014;5:115.
- Zhao D, Cui D, Wang B, et al. Treatment of early stage osteonecrosis of the femoral head with autologous implantation of bone marrow-derived and cultured mesenchymal stem cells. *Bone* 2012;50:325.
- Tabatabaee RM, Saberi S, Parvizi J, et al. Combining concentrated autologous bone marrow stem cells injection with core decompression improves outcome for patients with early-stage osteonecrosis of the femoral head: a comparative study. *J Arthroplasty* 2015;30:11.
- Gangji V, De Maertelaer V, Hauzeur J-P. Autologous bone marrow cell implantation in the treatment of non-traumatic osteonecrosis of the femoral head: five year follow-up of a prospective controlled study. *Bone* 2011;49:1005.
- Lim YW, Kim YS, Lee JW, et al. Stem cell implantation for osteonecrosis of the femoral head. *Exp Mol Med* 2013;45:e61.
- Liu Y, Liu S, Su X. Core decompression and implantation of bone marrow mononuclear cells with porous hydroxylapatite composite filler for the treatment of osteonecrosis of the femoral head. *Arch Orthop Trauma Surg* 2013;133:125.
- Yamasaki T, Yasunaga Y, Ishikawa M, et al. Bone-marrow-derived mononuclear cells with a porous hydroxyapatite scaffold for the treatment of osteonecrosis of the femoral head: a preliminary study. *J Bone Joint Surg Br* 2010;92:337.
- Pepke V, Kasten P, Beckmann NA, et al. Core decompression and autologous bone marrow concentrate for treatment of femoral head osteonecrosis: a randomized prospective study. *Orthop Rev (Pavia)* 2016;8:6162.
- Gardeniers J. A new international classification of osteonecrosis of the ARCO committee on terminology and classification. *ARCO News* 1992;4:41.
- Schmitt-Sody M, Kirchhoff C, Mayer W, et al. Avascular necrosis of the femoral head: inter- and intraobserver variations of Ficat and ARCO classifications. *Int Orthop* 2008;32:283.
- Ficat RP. Idiopathic bone necrosis of the femoral head. Early diagnosis and treatment. *J Bone Joint Surg Br* 1985;67:3.
- Papakostidis C, Tosounidis TH, Jones E, et al. The role of “cell therapy” in osteonecrosis of the femoral head. *Acta Orthop* 2015;87:72.
- Mont MA, Carbone JJ, Fairbank AC. Core decompression versus nonoperative management for osteonecrosis of the hip. *Clin Orthop Relat Res* 1996:169.
- Lau RL, Perruccio AV, Evans HMK, et al. Stem cell therapy for the treatment of early stage avascular necrosis of the femoral head: a systematic review. *BMC Musculoskelet Disord* 2014;15:156.
- Chahla J, Piuze NS, Mitchell JJ, et al. Intra-articular cellular therapy for osteoarthritis. *J Bone Joint Surg Am* 2016;98:1511.

33. Marcucio RS, Nauth A, Giannoudis PV, et al. Stem cell therapies in orthopaedic trauma. *J Orthop Trauma* 2015;29:S24.
34. Hendrich C, Franz E, Waertel G, et al. Safety of autologous bone marrow aspiration concentrate transplantation: initial experiences in 101 patients. *Orthop Rev (Pavia)* 2009;1:e32.
35. Hernigou P, Homma Y, Flouzat-Lachaniette CH, et al. Cancer risk is not increased in patients treated for orthopaedic diseases with autologous bone marrow cell concentrate. *J Bone Joint Surg Am* 2013;95-A:2215.
36. Peeters CMM, Leijns MJC, Reijman M, et al. Safety of intra-articular cell-therapy with culture-expanded stem cells in humans: a systematic literature review. *Osteoarthr Cartil* 2013;21:1465.
37. Yin H, Yuan Z, Wang D. Multiple drilling combined with simvastatin versus multiple drilling alone for the treatment of avascular osteonecrosis of the femoral head: 3-year follow-up study. *BMC Musculoskelet Disord* 2016;17:344.
38. Fang T, Zhang EW, Sailes FC, et al. Vascularized fibular grafts in patients with avascular necrosis of femoral head: a systematic review and meta-analysis. *Arch Orthop Trauma Surg* 2013;133:1.
39. Zeng Y-R, He S, Feng W-J, et al. Vascularised greater trochanter bone graft, combined free iliac flap and impaction bone grafting for osteonecrosis of the femoral head. *Int Orthop* 2013;37:391.
40. Amini AR, Laurencin CT, Nukavarapu SP. Bone tissue engineering: recent advances and challenges. *Crit Rev Biomed Eng* 2012;40:363.
41. Arvidson K, Abdallah BM, Applegate LA, et al. Bone regeneration and stem cells. *J Cell Mol Med* 2011;15:718.
42. Caplan AI. Mesenchymal stem cells. *J Orthop Res* 1991;9:641.
43. Connolly JF. Clinical use of marrow osteoprogenitor cells to stimulate osteogenesis. *Clin Orthop Relat Res* 1998:S257.
44. Dominici M, Le Blanc K, Mueller I, et al. Minimal criteria for defining multipotent mesenchymal stromal cells. The International Society for Cellular Therapy position statement. *Cytotherapy* 2006;8:315.
45. Dimitriou R, Jones E, McGonagle D, et al. Bone regeneration: current concepts and future directions. *BMC Med* 2011;9:66.
46. Giannoudis PV, Calori GM, Begue T, et al. Bone regeneration strategies: current trends but what the future holds? *Injury* 2013;44:S1.
47. Grayson WL, Bunnell BA, Martin E, et al. Stromal cells and stem cells in clinical bone regeneration. *Nat Rev Endocrinol* 2015;11:140.
48. Muschler GF, Nakamoto C, Griffith LG. Engineering principles of clinical cell-based tissue engineering. *J Bone Joint Surg Am* 2004;86-A:1541.
49. Muschler GF, Midura RJ. Connective tissue progenitors: practical concepts for clinical applications. *Clin Orthop Relat Res* 2002;1:66.
50. Muschler GF, Midura RJ, Nakamoto C. Practical modeling concepts for connective tissue stem cell and progenitor compartment kinetics. *J Biomed Biotechnol* 2003;2003:170.
51. Muschler GF, Nitto H, Boehm CA, et al. Age- and gender-related changes in the cellularity of human bone marrow and the prevalence of osteoblastic progenitors. *J Orthop Res* 2001;19:117.
52. Patterson TE, Kumagai K, Griffith L, et al. Cellular strategies for enhancement of fracture repair. *J Bone Joint Surg Am* 2008;90(Suppl 1):111.